

**University Medical Center Hamburg-Eppendorf**

**Department of Urology**

**Director: Prof. Dr. med. Margit Fisch**

**HIGH URINARY DIVERSION (TRANSVERSE COLON POUCH-  
TRANSVERSE COLON CONDUIT)**

**Dissertation**

**Submitted for fulfillment of M.D. Degree in Urology from the Faculty of  
Medicine, Hamburg University**

**By**

**Khalid Ahmed Mahmoud Sayed Ahmed**

**From Elmenufeyia-Egypt**

**Hamburg 2010**

**Angenommen von der Medizinischen Fakultät am: 8.4.2010**

**Veröffentlicht mit der Genehmigung der Medizinischen Fakultät der Universität  
Hamburg am:**

**Prüfungsausschluss, Vorsitzender: Prof Dr. Margit Fisch**

**Prüfungsausschluss, 1. Gutachter: PD Dr. Volkmar Müller**

**Prüfungsausschluss, 2. Gutachter: PD Dr. Martin Bockhorn**

***Dedication***

*This work is dedicated to my parents; my father, who learned me that everything in the life can be possible and my mother, who learned me that everything in the life can be beautiful and enjoyable.*

---

## Contents

<b>1. Introduction.....</b>	<b>1</b>
<b>2. Basic consideration.....</b>	<b>3</b>
2.1. Effect of irradiation on the tissue.....	3
2.2. History of large bowel use in urinary diversion.....	4
2.2.1. Incontinent urinary diversion.....	4
2.2.2. Continent cutaneous reservoirs.....	5
2.3. Implantation of the ureter in the colonic reservoir.....	6
2.4. Surgical Anatomy of the Colon (Skandalakis', 2004).....	7
2.4.1. Length and Diameter of the Large Intestine .....	7
2.4.2. Vascular Supply .....	7
2.4.3. Venous drainage.....	8
2.4.4. Hepatic Flexure, Transverse Colon, Splenic Flexure, and Transverse Mesocolon.....	9
2.4.5. Arterial Supply, Venous Drainage .....	10
2.5. Indications and contraindications of transverse colon Urinary diversion.....	11
<b>3. Aim of the study .....</b>	<b>13</b>
3.1. Questions to be answered by this study.....	13
<b>4. Patients and methods.....</b>	<b>14</b>
4.1 Patients.....	14
4.2 The malignant indications of transverse colon diversion.....	14
4.3 Benign indications of high urinary diversion.....	16
4.4 History of irradiation.....	16
4.5 The inclusion criteria.....	16
4.6 The exclusion criteria.....	17
4.7 Exclusion criteria of transverse colon pouch (in which transverse	



colon conduit is indicated).....	17
4.8. Transverse colon pouch (Mainz III pouch).....	18
4.8.1. Preoperative preparation .....	18
4.8.2. Suture materials.....	18
4.8.3. Operative technique.....	19
4.9. Transverse colon conduit.....	25
4.9.1. Preoperative preparation.....	25
4.9.2. Surgical technique.....	25
A) Instruments required .....	25
b) Suture material.....	25
c) Surgical steps.....	25
e) Surgical Tips.....	31
4.9.3. Postoperative care.....	32
4.10 Follow up.....	32
4.11. Data collection.....	33
4.11.1 The questionnaire.....	34
<b>5. Results.....</b>	<b>37</b>
5.1. Age and sex distribution.....	37
5.2. History of irradiation.....	37
5.3. Operative evaluation.....	38
5.4. Early postoperative evaluation.....	38
5.4.1. Hospital stay.....	38
5.4.2. Early postoperative complications.....	38
5.5. Follow up.....	39
5.5.1. Biochemical evaluation and complications during follow up .....	39
5.7. Items specific to transverse colon pouch:	
5.7.1. Pouch capacity.....	40
5.7.2. Continence.....	41
5.7.3. Poucho-ureteral reflux.....	41
5.8. Quality of life.....	42

5.9. Death during Follow up.....	43
<b>6. Discussion.....</b>	<b>44</b>
6.1. Indications.....	44
6.2. Complications.....	48
6.3. Uretero-intestinal anastomosis.....	59
6.4. Quality of life.....	63
<b>7. Conclusion and recommendations.....</b>	<b>66</b>
<b>8. References .....</b>	<b>67</b>
<b>9. Acknowledgements.....</b>	<b>85</b>
<b>10. Curriculum vitae (C.V.) .....</b>	<b>86</b>
<b>11. Declaration .....</b>	<b>87</b>

---

**List of abbreviations**

cm	Centimeter
UD	Urinary diversion
Ed	Edition
F	French
ft	Feet
Gy	Gray
IVU	Intravenous urography
K	Potassium
M	Meter
meq/l	Milliequivalent per Liter
mg/dl	Milligram per deciliter
ml	Milliliter
Na	Sodium
PE	Pelvic exenteration
QLQ	Quality of life questionnaire
QOL	Quality of life
RVVF	Radiation induced vesico-vaginal fistula
SF	Short form
TAP	Transverse ascending pouch
TDP	Transverse descending pouch
VS	Versus
WHO	World Health Organisation

## 1. Introduction

Urinary diversion in previously irradiated patients has proven to be a challenge which has been addressed with several different techniques. There is a high rate of early and late complications using small bowel segments and ileocaecal reservoirs. Based on the high risk of failure in reconstructive surgery in the irradiated field, and on the high complication rate after using irradiated tissue for urinary diversion, the 'avoidance' principle was adopted with unirradiated large bowel segments being used for continent urinary diversion (Schmidt et al. 1985). With the cranial position outside the irradiation field transverse colon fulfills the demand to be unirradiated, which is of utmost importance for segment to be used for urinary diversion. Not only the transverse segment but also the ascending or the descending colon can be used which offer an adaptation to individual patient and an adaptation to the individual patient situation. The ascending and the descending colon are located in the retroperitoneal position. The transverse ascending pouch (TAP) and transverse descending pouch (TDP) were introduced in patients with previous pelvic irradiation therapy. There is no limitation as regard to the short ureters as a part of the colon the segments offers feasibility for antirefluxive as well as refluxive ureteral implantation (Mogg 1987). Another advantage of the technique is preservation of the ileocaecal valve for limiting adverse effects related to an increased stool frequency; there is also no risk of vitamin B12 deficiency, as it is associated with the use of small bowel segments for urinary diversion (Sagalowsky et al. 2002).

Transverse colonic conduit has been more and more implemented in the patients with urologic or gynecological malignancies and additional radiotherapy (Morales and Golimbu 1975). This technique is indicated in Patients with total damage of the ureters by irradiation or retroperitoneal fibrosis and in patients with recurrent urothelial tumor in a single kidney, direct anastomosis of the conduit to the renal pelvis represents an option (pyelotransverse pyelocutaneostomy) (Fisch et al. 1991). Also in cases of recurrent urothelial tumors and a single kidney a direct anastomosis of a conduit to the renal pelvis allows direct endoscopic access to the calices and in cases in which the continent cutaneous diversion is contraindicated as

inability of self catheterization or renal insufficiency with elevated serum creatinine level ( $>2$  mg/dl).

The excellent results of these types of urinary diversion in patients with previous pelvic irradiation therapy caused us to do this retrospective study evaluating it and the suggestion of its use not only under special circumstances but also as an alternative form of urinary diversion in unirradiated patients.

## **2. Basic considerations**

### **2.1. Effect of irradiation on the tissue**

Radiotherapy is a known treatment modality for some malignant neoplasms. Radiotherapy for cervical carcinoma can result in the appearance of urologic complications such as actinic cystitis and urinary fistulas. Considering the high prevalence of cervical carcinoma and wide use of radiation therapy, the management of the vesicovaginal fistula becomes an important issue for modern female urology.

When radiation is terminated, fibrosis occurs in the bladder lamina propria. Due to these changes, hyalinization of the connective tissues develops. Histologic examinations show the presence of large bizarre fibroblasts, which are described as radiation fibroblasts (Berthrong 1986). Small and medium arteries are affected by radiation-induced obliterative arteritis. Vascular damage of bladder tissue leads to atrophy or necrosis of the bladder epithelium, which causes ulceration or the formation of fissures. The majority of fistulae become apparent 1.5–2 yr after termination of radiotherapy. Some fistulas may not appear for many years after treatment (Raz et al. 1992). The bladder function as a reservoir can be lost, and these problems are difficult to correct surgically (Beckley et al. 1982). Maier et al. 1997 reported that 1.24% (133/ 10709) of the patients, who underwent radiation therapy suffered severe urologic complications such as vesicovaginal fistula that required surgical intervention. The presence of a typical RVVF is preceded by radiation cystitis, fever, and hematuria. These symptoms change dramatically with the sudden presence of vesicovaginal fistula. The tissues surrounding the fistula are indurated and bleed easily. Ulcerations of mucosa and areas of necrosis on the bladder and vaginal walls are the typical finding during clinical evaluations of RVVF patients. It is obvious that the success of any plastic surgery is extremely limited in this situation due to lack of tissues.

Eifel et al. 2003 showed that there is 9.3% probability of having a major urinary tract or gastrointestinal complication after cervix radiation therapy. There was a subsequent continuous risk of approximately 0.34% per year, resulting in risk of major complications of 11.1% at 10 yr, 13% at 15 yr, and

14.4% at 20 yr. Despite improvements, patients treated with radiation as adjuvant or definitive therapy have shown unavoidable side-effects. Radiation cystitis may be severe enough to necessitate urinary diversion. Early experiences with continent cutaneous diversion in patients undergoing salvage surgery after radiation failure were disappointing because it was associated with a high operative morbidity and mortality (Lund et al. 1980 and Edsmyr et al. 1970).

The small intestine and the ascending, as well as descending colon experience the damaging effects of radiation, particularly loss of vascularization and the development of obliterating endarteritis. Thus, these segments should not be used in creating urinary reservoirs because complications such as stricture of the stoma, enteroenteric fistulas, and dehiscence of ureterointestinal anastomosis can occur (Perez et al. 1999). The transverse colon does not suffer the damaging effects of pelvic radiation because of its high position in the abdomen. Moreover, it presents with an adequate blood supply for an appreciable extension, which allows ureterointestinal anastomosis using the antireflux technique (Beckley et al. 1982).

## **2.2. History of large bowel use in urinary diversion**

### **2.2.1. Incontinent urinary diversion**

In 1940 Bricker constructed a sigmoid colon conduit in four patients. He placed the urinary stoma close to the colostomy, leading to poor results (Bricker et al. 1950). In 1952 Übelhör of Vienna placed the colostomy on the left side of the abdomen and placed the stoma in the right side (Übelhör et al. 1952).

In 1950, Bricker and Eiseman published two cases in which they used the terminal ileum and the ascending colon as a pouch (Bricker et al. 1950), this reservoir was completely incontinent and the patients had to use a Rutzen bag appliance. Zinman and Libertino of Boston reintroduced the ileocoecal conduit in 1975. They anastomosed the ureters to the terminal ileum and augmented the ileocoecal valve by approximating the cecum around the

ileum for a length of 1 cm to prevent reflux (Zinman and Libertino 1975). This technique was not adopted into clinical use.

The use of transverse colon as urinary conduit was first mentioned by Nelson in 1969 (Nelson 1969). Then in 1975 Schmidt et al and Morales and Golimbu published the results of the transverse colon conduit in the patients, who had undergone prior radiotherapy for pelvic malignancy, the complication rate was 20-51% in this highly selected group of patients (Morales 1975). Today transverse colon conduit is the procedure of choice in patients with a prior history of radiotherapy (Stien et al. 2008).

### **2.2.2. Continent cutaneous reservoirs**

#### **a) The ileocoecal segment:**

In 1908, Verhoogen was the first surgeon to create the cutaneous continent reservoir using the ileocoecal segment with the appendix as a continence mechanism (Verhoogen et al. 1908) two years later; Makkas implanted the entire trigone into the ileocoecal reservoir. Unlike Verhoogen, he performed a side-to-side anastomosis of the ileum to the midtransverse colon to obtain a larger reservoir (Makaas 1910).

In 1912 Lengemann modified the technique by using 30 cm of the ileum followed by experimental implantation of the trigone in the second operation.

In 1946 Gallo of the Argentina published a case report on a patient with ileocoecal reservoir and appendiceal continence mechanism, who survived 13 years a normal upper urinary tract was found in the autopsy (Gallo 1946).

In 1984 Mason published his results with the coecum as a reservoir and an intussuscepted ileal nipple for continence. The most frequent complication was the malfunction of the nipple valve with urinary leakage and difficult catheterization (Mason et al. 1984).

In 1985 Thüroff et al of Mainz and Roland et al. of Indianapolis reported their promising initial results in World Journal of Urology, after maen follow-up of 7.6 years in 800 patients with an ileocoecal reservoir (Mainz pouch I) (Thüroff et al. 1985).

#### **b) Colon segments**

In 1989 Bihrlé et al. of Indianapolis described the technique using the continent transverse colon reservoir in animals. They used a detubularized



segment of the transverse colon, antireflux ureter implantation, and tunneled the detubularized gastric segment to create the new continence mechanism. They use this pouch mainly in patients, who had prior radiotherapy to the pelvis. Stomatitis of the gastric segment was treated with H2 blocker (Bihrlé et al. 1989).

In 1996 Fisch et al described the technique of the transverse ascending colon pouch (TAP) or the Transverse- descending colon pouch (TDP) used in radiation-treated patients (Fisch et al. 1996).

### **2.3. Implantation of the ureter in the colonic reservoir**

In 1936 Hinman and Weyrauch critically reviewed different surgical principles of uretero-intestinal anastomosis in the last century. More than 60 methods were cited. Multiplicity of techniques usually implies that none of these methods was satisfactory or widely accepted. All poor results were attributed to two significant problems: strictures developing at the anastomosis site and / or reflux of colonic contents to the upper urinary tract (Hinman and Weyrauch 1936).

In an attempt to overcome the high incidence of anastomosis stricture Nesbit proposed the direct elliptical mucosa to mucosa anastomosis of the spatulated ureter to the sigmoid colon (Nesbit 1960). Two years later Cordonnier modified this technique by adding second layer to the anastomosis between the intestinal serosa and the ureteric adventitia (Cordonnier 1962).

Leadbetter introduced a combined procedure. He described the submucosal tunnel of Coffey to prevent reflux and the mucosa to mucosa anastomosis of Nesbit to avoid the development of strictures (Leadbetter 1951 and Pannek 1980)

A few years later Goodwin et al described a similar technique in which the anastomosis is performed from within the bowel (Goodwin et al. 1953).

Strikler described another modification to create a submucosal tunnel (Pannek and Senge 1953).

Pagano incised a line for 4-5 cm and separated the seromuscular layer from the mucosa on both sides of the tinea laterally as far as the mesenteric border creating a single wide submucosal trough, Nevertheless the incidence of ureteric obstruction following ureterosigmoidostomy using a submucosal

tunnel remained significant ranging between 13% and 32% (Pagano 1980). Accordingly the question of having a nonobstructed and a non-refluxing uretero-colonic anastomosis remained unsolved.

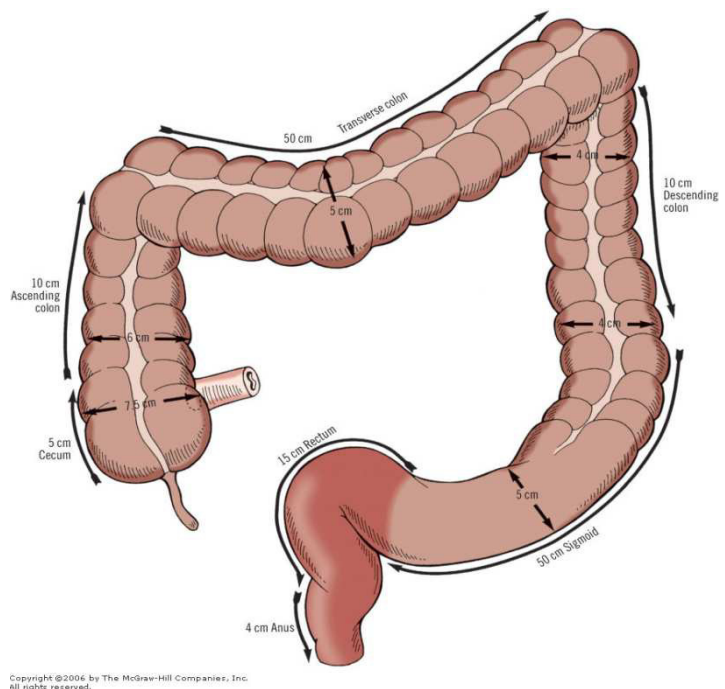
## 2.4. Surgical Anatomy of the Colon (Skandalakis' 2004)

### 2.4.1. Length and Diameter of the Large Intestine

According to Gray's Anatomy 37th ed., the length of the large bowel is in average about 1.3-1.8 m. (Williams et al. 1989). The length from the end of the distal ileum to the anus is about 1.5 m. Goligher estimated the length of the colon to be 4,5 ft (1.25 m). (Goligher et al.1969).

Figure (1): Length and diameter of the large intestine. (From Skandalakis JE, Gray SW and Rowe JS Jr.)

The caliber of the large bowel is greater close to the cecum; it gradually gets smaller toward the rectum, and then dilates again at the rectal ampulla just above the surgical anal canal. A sigmoid colon loop is



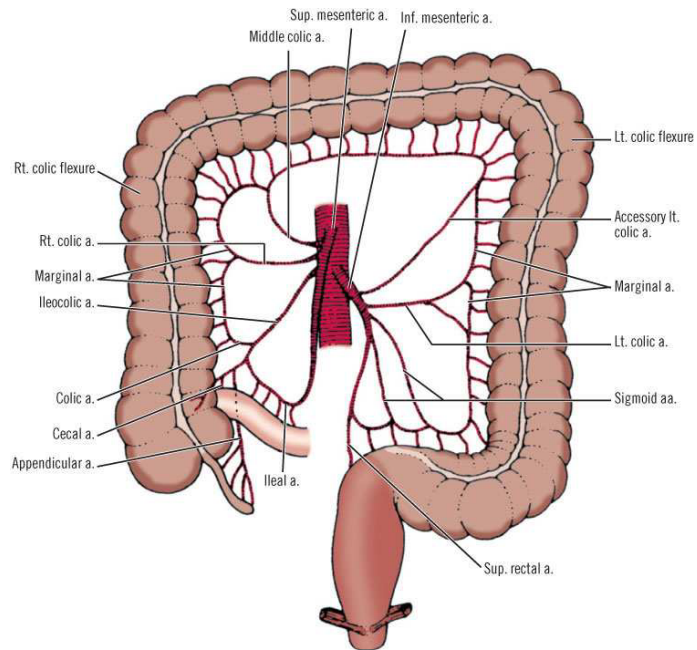
occasionally as wide as a loop of terminal ileum. Sadahiro et al. 1992 in a study of Japanese patients reported that the transverse colon was the largest in length and surface area of the 6 segments of large intestine.

### 2.4.2. Vascular Supply

The large intestine is supplied by the superior and inferior mesenteric arteries and branches of the internal iliac (hypogastric) artery; it is drained by the superior and inferior mesenteric veins and tributaries to the internal iliac vein.

Figure (2): Schema of the arterial blood supply to the large intestine. There are many variations of this basic pattern. (From Skandalakis JE, Gray SW and Rowe JS Jr. Anatomical Complications in General Surgery. New York: McGraw-Hill 1983).

Three weak points involving the vascular supply to the colon have been described. Sudeck's critical point, involving the vascular supply which is located between the junction of the sigmoid and superior hemorrhoidal arteries, was thought to be a particularly tenuous anastomotic area such



Copyright © 2006 by The McGraw-Hill Companies, Inc.  
All rights reserved.

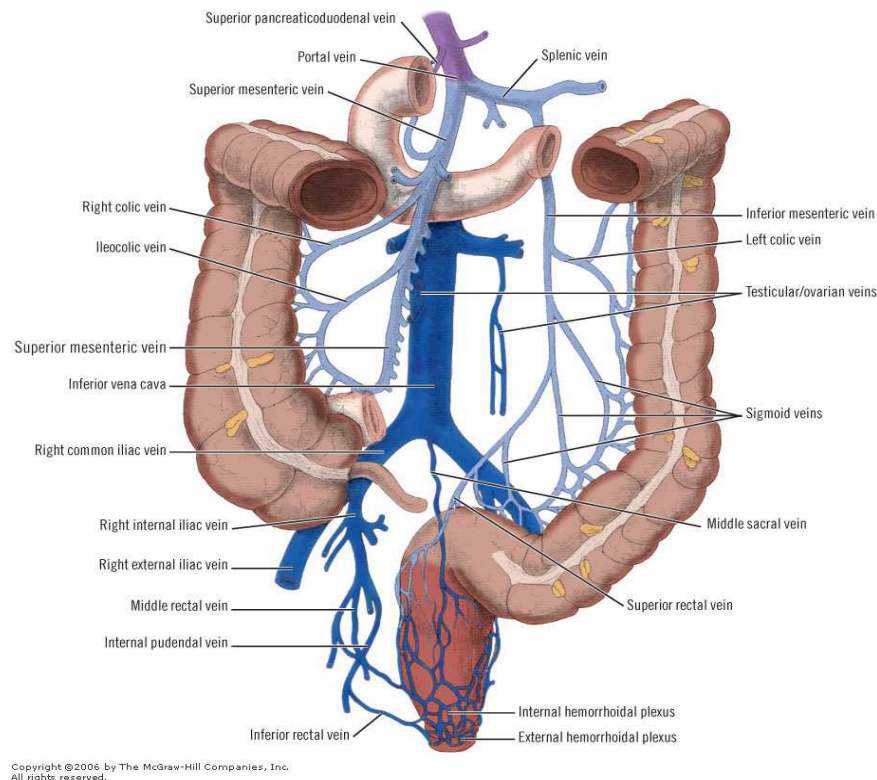
that if the colon were transected in this region, the anastomosis would heal with difficulty, because the blood supply might be compromised. Similarly, the midpoints between the middle colic and right colic arteries and between the middle colic and left colic arteries also have somewhat tenuous anastomotic communications. Although anastomoses in these areas generally heal well, provided the principles of proper technique are adhered to, it is usually wise to select an area for the anastomosis to one side of these points. (Douglass et al. 2007)

### 2.4.3. Venous drainage

Veins of the colon follow the arteries. On the right (The cecum, ascending colon and right transverse colon), the veins join to form the superior mesenteric vein. Veins of the hepatic flexure and the right portion of the transverse colon enter the gastroepiploic vein or the anterior superior pancreaticoduodenal vein.

Figure (3):

Venous drainage of colon and rectum. Dark blue, systemic venous drainage. Light blue, portal venous drainage. (Modified from Gordon PH, Nivatvongs S (eds). Principles and Practice of Surgery for the Colon, Rectum and Anus. St. and Louis MO: Quality Medical Publishing 1992)



#### 2.4.4. Hepatic Flexure, Transverse Colon, Splenic Flexure, and Transverse Mesocolon:

The hepatic flexure is located under the 9th and 10th costal cartilages in the vicinity of the midaxillary line between the anterior surface of the lower half of the right kidney and the inferior surface of the right hepatic lobe. The gallbladder is located anteriorly, and the duodenum is located posteriorly. The transverse colon begins where the colon turns sharply to the left (the hepatic flexure), just beneath the inferior surface of the right lobe of the liver. It ends at a sharp upward and then downward bend (the splenic flexure) related to the posterolateral surface of the spleen. The tail of the pancreas is above. The anterior surface of the left kidney lies medially. The transverse colon, unlike the ascending and descending colon, has a mesentery, which has fused secondarily with the posterior wall of the omental bursa. At the beginning of the mesentery, there may be additional bands of peritoneum, the hepatocolic and cystocolic ligaments. These are adhesion bands, not persistent remnants of the ventral mesentery. At the splenic flexure, the colon is supported by the phrenocolic ligament, a part of the left side of the transverse mesocolon. Between the hepatic and splenic flexures, the transverse colon hangs in a U- or V-shaped curve. It may lie above the

umbilicus, but is often lower, even extending into the true pelvis. The transverse colon varies with individuals and with body position. The transverse mesocolon is formed by a double peritoneal fold, which extends upward and attaches to the anterior pancreatic border, suspending the transverse colon from the pancreas. It ranges in length from 3 to 12 cm. The transverse mesocolon contains the middle colic artery and vein, and lymph nodes as well as nerves. Occasionally, the superior fold of the transverse mesocolon is fixed by adhesions to the posterior wall of the stomach.

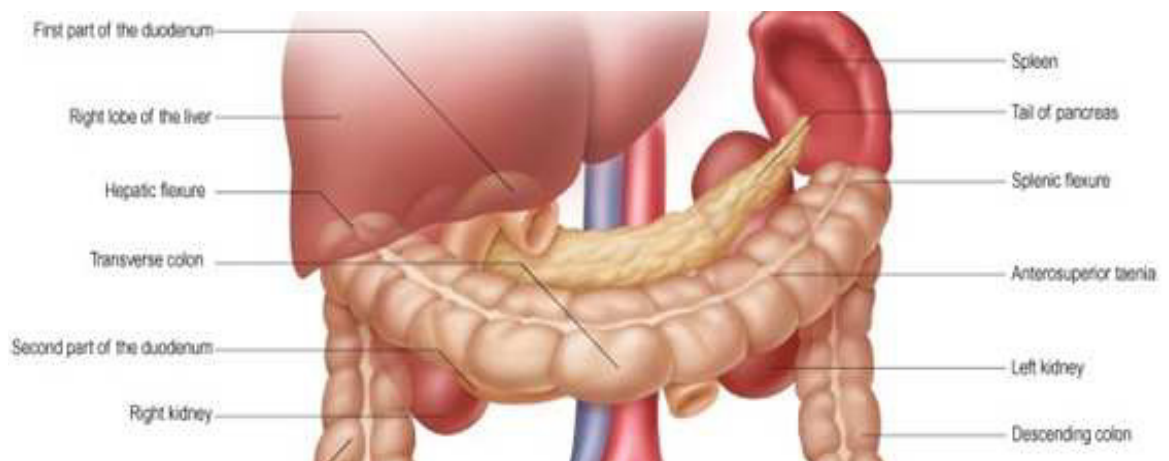


Figure (4): Overview of the abdominal colon and its relations. Grays Anatomy 39e. [www.graysanatomyonline.com](http://www.graysanatomyonline.com).

The splenic flexure has an acute angle. It is located higher than the hepatic flexure, at the level of the 8th interspace in the midaxillary line. This high position is due not only to the small left hepatic lobe, but also to the multiple splenic ligaments and other ligaments in its vicinity. The splenic flexure is related posteriorly to the left kidney and anteriorly to the left costal arch and occasionally to the stomach.

#### 2.4.5. Arterial Supply, Venous Drainage

In the "typical" arrangement, the right colic artery bifurcates into ascending and descending branches. The ascending branch anastomoses with the right branch of the middle colic artery. The descending branch anastomoses with the ileocolic artery. The left colic artery also bifurcates; its ascending branch anastomoses with the left branch of the middle colic artery, and its descending branch anastomoses with the first branch of the sigmoid artery.

The main blood supply of the transverse colon is the middle colic artery, but the ascending branch of the left colic artery contributes circulation for the distal part of the transverse colon. Anatomically, the entrance of the middle colic artery into the antimesenteric border of the transverse colon is very close to the pancreatic neck. If adhesions of benign or malignant origin are present in this area, this is another point of danger. The middle colic artery bifurcates from 3 cm to 11 cm from the colonic wall, and may be absent in 5-8 percent of individuals. In most cases, the middle colic artery originates from the superior mesenteric artery. It can arise as a stem from the inferior pancreaticoduodenal artery, right hepatic artery, jejunal artery, or other branches take origin. It may be absent (Robillard et al. 1947). The venous return is formed by right and left networks. The right network drains into the right gastroepiploic vein or the superior mesenteric vein. The left network drains into the inferior mesenteric vein.

## **2.5. Indications and contraindications of transverse colon urinary diversion**

Beside the prior history of irradiation transverse colon diversion is also indicated in absolute or functional loss of the urinary bladder (patients with muscle-invasive bladder cancer, local tumour recurrence of gynaecological malignancies, irreparable neurogenic bladder disorders after failed conservative management). The technique can also be used in patients with complete pelvic exenteration requiring urinary diversion and colostomy (Leissner et al. 2006).

### **Transverse colon conduit is specifically indicated in:**

- a) Patients with total damage of the ureters by irradiation or retroperitoneal fibrosis and in patients with recurrent urothelial tumor in a single kidney. Direct anastomosis of the conduit to the renal pelvis represents an option (pyelotransverse pyelocutaneostomy) (Fisch et al. 1991).
- b) Patients with recurrent urothelial tumors and a single kidney. A direct anastomosis of a conduit to the renal pelvis allows direct endoscopic access to the calices.
- c) Patients with inability of self catheterization.



d) Patients with renal insufficiency with elevated serum Creatinine levels (>2 mg/dl).

**Transverse colon pouch is preferred as high urinary diversion:**

In young patients a continent transverse pouch represent an alternative to transverse colon conduit (Leissner et al. 2000).

**Contraindications of transverse colon diversion**

Irradiation of the upper abdomen, status postextensive colon resection and ulcerative colitis (Hohenfellner and Fisch 2004)

**Specific contraindications of transverse colon pouch** (Leissner et al. 2006):

- a) Renal insufficiency with elevated serum Creatinine levels (>2 mg/dl).
- b) Poor compliance (Patient compliance is mandatory for regular follow-up visits, including measurement of base excess).

**3. Aim of the study**

To evaluate the use of the transverse colon pouch (Mainz III) and transverse colon conduit as the encouraging results of these types of diversion suggest that their indications could be extended.

**3.1. Questions to be answered by this study**

- 1) What are the results of the use of the transverse colon urinary diversion (high urinary diversion) in previously irradiated patients?
- 2) What are the results of these types of urinary diversions in comparison to other types?
- 3) Are these types of diversion suitable to be generalized to all patients in need of urinary diversion?



#### 4. Patients and methods

This study was carried out in Aklepios Klinik Harburg, Hamburg and University Medical Center Hamburg-Eppendorf. It includes retrospective evaluation of the outcome of 43 patients with high urinary diversions (using transverse colon segments).

##### 4.1. Patients

In this study 43 patients were included; 23 patients with transverse colon pouch (Mainz III pouch) and 20 patients with transverse colon conduit. Patients with transverse colon pouch included 15 female and 8 males. Patients with transverse colon conduit included 10 males and 10 females. The age of the patients included in this study ranged from 19 to 81 years. Overall, 40 of the patients had a malignant disease and 3 a benign disease.

##### 4.2. The malignant indications of transverse colon diversion

Indication	No. of patients	Presentation
Cancer of the cervix	20	Vesico-vaginal fistula (n=10) Post irradiation contracted bladder (n=4) Combined vesico-vaginal and recto-Vaginal fistula (n=2) Bilateral ureteral stricture (n=1) Reccurence+Bladder infiltration (n=2) Cancer bladder (associated) (n=1)
Cancer of the prostate	8	Incontinence+ Contracted bladder (n=4) Recurrent bladder neck contraction Contracted bladder (n=3) Recto-vesical fistula (n=1)
Cancer of the rectum	4	Recto-vesical fistula (n=2) Bladder invasion (n=1) Contracted bladder (n=1)
Cancer of the bladder	3	Reccurence (n=2) Invasin of both ureters (n=1)
Pelvic bone sarcoma	1	Contracted bladder +Wound fistula (n=1)
Rhabdomyosarcoma of the prostate	2	Post irradiation contracted bladder (n=2)
Endometrial carcinoma	1	Vesico-vaginal-intestinal fistula (n=1)
Vaginal carcinoma	1	Reccurence+Bladder infiltration (n=1)

Table (1): Shows the malignant indications of high urinary diversion.

From the whole number of patients, 40 patients had malignant indications of high urinary diversion (93%)

These indications include the following

Gynecologic malignancy in 22 patients (55%), including:

20 patients with cancer of the cervix presented with vesico-vaginal fistula in 10 cases.

postirradiation contracted bladder in

4 cases, recurrence with bladder infiltration in 2 cases, combined vesico-vaginal and

recto-vaginal fistula in 2 cases, bilateral

ureteral stricture in one case and

associated bladder cancer in one case.

*One case of endometrial carcinoma presented with bladder infiltration and vesico-vaginal-intestinal fistula.*

*One case of vaginal cancer presented with recurrence and bladder infiltration after primary surgical management.*

Malignant tumors of prostate in 10 patients (25%) including:

*8 patients with cancer of the prostate presented by:*

*Urinary incontinence associated with post irradiation contracted bladder in 4 cases, recurrent bladder*

*neck contraction associated with post irradiation contracted bladder in 3 cases and one case of recto-vesical fistula .*

*2 patients of rhabdomyosarcoma of the prostate presented with postirradiation contracted bladder.*

Cancer rectum in 4 patients (10%) including:

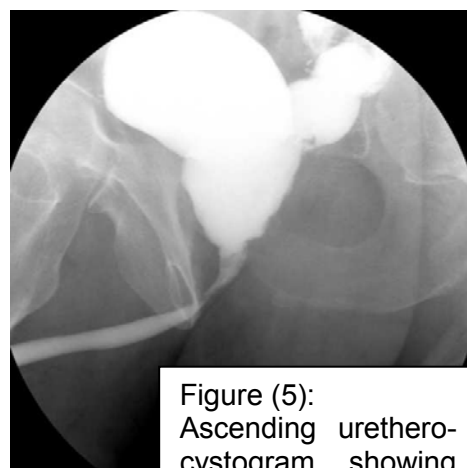

Figure (5):  
Ascending urethro-  
cystogram showing  
vesico-rectal fistula.

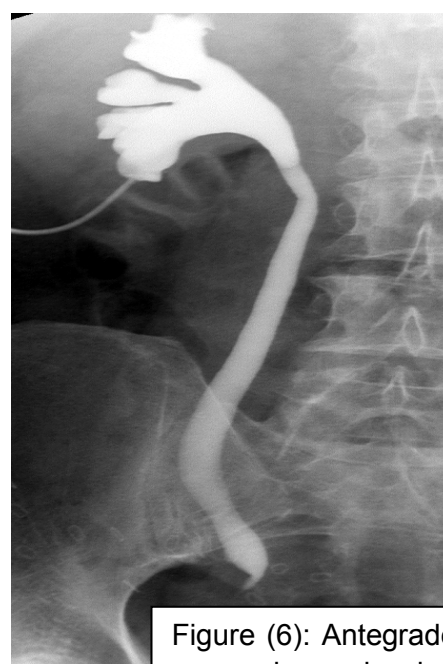

Figure (6): Antegrade  
urography showing  
severe stricture in  
lower ureter due to  
malignant infiltration.

*2 patients presented with recto–vesical fistula; one case presented with postirradiation contracted bladder and one case presented with bladder infiltration.*

Bone sarcoma in one patient (2.5%) including  
*One case of sarcoma of pelvic bone presented with postirradiation contracted bladder and wound fistula*

#### 4.3. Benign indications of high urinary diversion

Benign indications were; one case hyper-reflexive bladder after polytrauma and two cases of neurogenic bladder dysfunction.

#### 4.4. History of irradiation

36 patients (83.7%) had a history of radiotherapy (32–66 Gy) before the urinary diversion.

7 Patients (16.3%) had no history of radiotherapy before the urinary diversion

#### 4.5. The inclusion criteria

(1) Patients with absolute or functional loss of the urinary bladder

(2) Patients with muscle-invasive bladder cancer or local tumour recurrence of gynecological malignancies.

(3) Patients with irreparable vesical fistula.

(4) Neurogenic bladder disorders after failed conservative management.

(5) The technique can also be used in patients with complete pelvic exenteration requiring urinary diversion and colostomy regarding that the patient is fit for surgery.

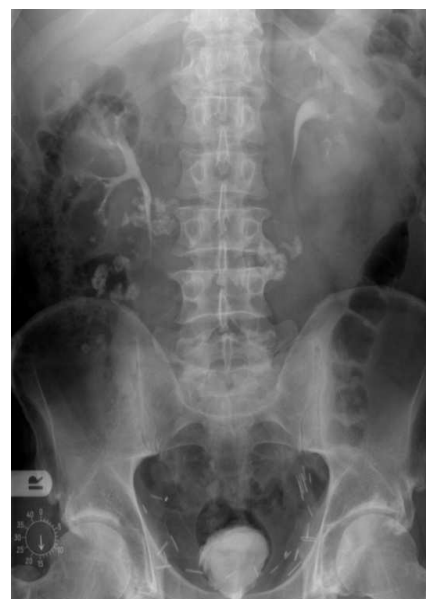

Figure (7): IVU of patient with urinary incontinence and contracted bladder after radiation therapy of cancer of

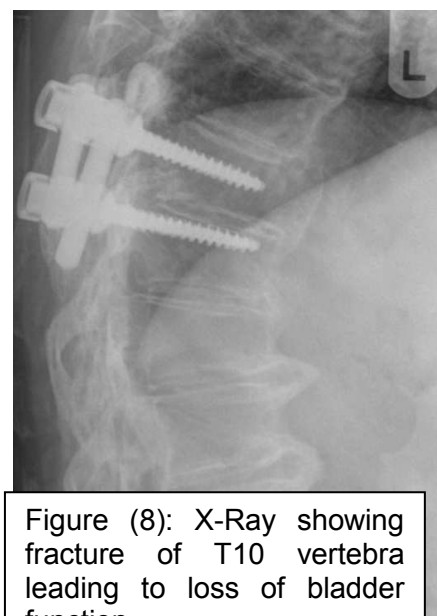


Figure (8): X-Ray showing fracture of T10 vertebra leading to loss of bladder function.

Patients should understand the problems and risks associated with self-catheterization (in cases of continent cutaneous diversion) and should be assessed for compliance.

Patient compliance is mandatory for regular follow-up visits, including measurement of base excess.

Dilatation of the upper urinary tract with normal kidney function is not a contraindication for transverse colon pouch.

#### **4.6. The exclusion criteria**

- 1) Patient refusing operation.
- 2) Patient unfit for surgery.
- 3) Short bowel syndrome.
- 4) Abnormalities of the colon (Diverticle disease or stenosis).
- 5) History of colorectal cancer.
- 6) History of irradiation of upper abdomen.

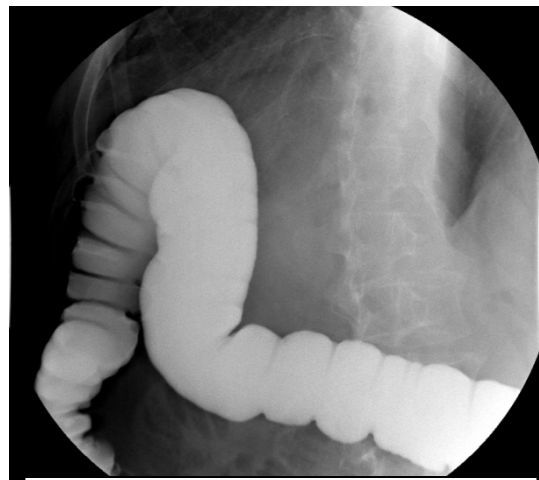


Figure (9): Preoperative colon contrast enema.

#### **4.7. Exclusion criteria of transverse colon pouch (in which transverse colon conduit is indicated)**

- 1) Poor compliance.
- 2) Renal insufficiency with elevated serum creatinine levels ( $>2$  mg/dl).
- 3) If self catheterization is expected to be impossible or difficult.

#### 4.8. Transverse colon pouch (Mainz III pouch) (Leissner et al. 2006)

##### 4.8.1. Preoperative preparation

- IVU.
- Renal scintigraphy if there is upper urinary tract dilatation. Nephrectomy should be considered, when the split renal function of one side is < 20% of total renal function.
- A contrast-medium enema to exclude diverticular disease or stenosis of the colon. Also estimate the colon length available and decide on a TAP or TDP (the skin incision circumnavigates the umbilicus on the contralateral side), in suspected cases colonoscopy is indicated.
- Bowel preparation with mechanical clean out 1 day before surgery.

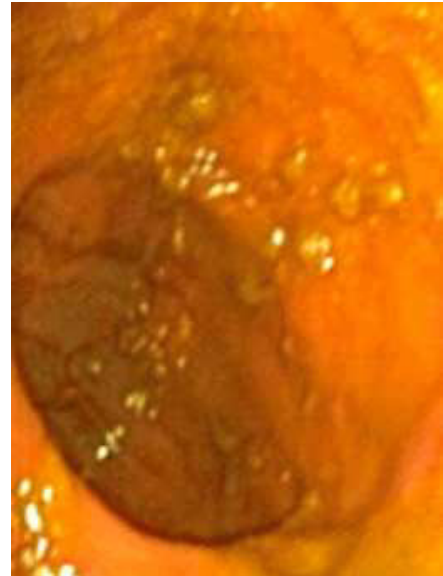

Figure (10): Colonoscopy done as preoperative evaluation.

##### 4.8.2. Suture materials

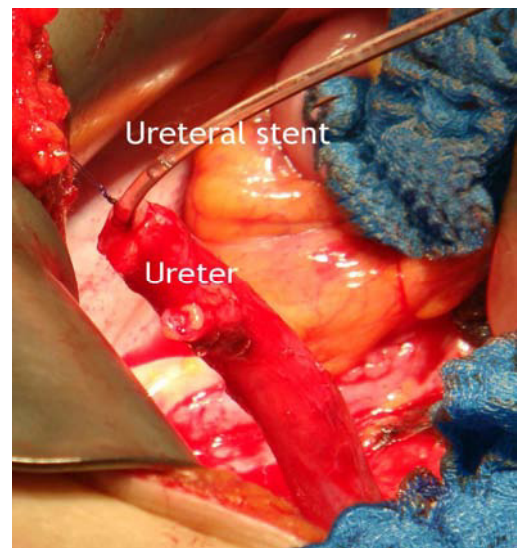
- Ureteric implantation: Monofilament sutures 5×0 (e.g. poliglecaprone, polyglyconate).
- Pouch wall: Monofilament sutures with straight needle 4×0 (polydioxanone)
- Fixation of stents: e.g. polyglactin rapid 4×0.
- Umbilical funnel: Monofilament sutures 3×0 (e.g. poliglecaprone, polydioxanone).
- Creation of efferent segment: Monofilament absorbable sutures for mucosa (e.g. poliglecaprone 5×0), nonabsorbable sutures for seromuscular layer (e.g. polypropylene 3×0).

#### 4.8.3. Operative technique

- A midline laparotomy is made from the xiphoid to the pubic symphysis with circumnavigation of the umbilicus on the right side for the TDP and on the left side for the TAP. This decision is made based on the preoperative enema.
- In patients who have undergone previous midline laparotomies, the same skin incision should be used to avoid umbilical necrosis and to create a wellvascularized umbilical stoma.
- Small and large bowel are mobilized carefully to avoid serosal lesions and the need for bowel resections.
- Ureters are dissected out of the retroperitoneal tissue, where they are often impacted and obstructed in a fibrous mass after irradiation.

The ureteric stumps are shortened up to a level at which arterial capillary bleeding, spontaneous peristalsis and urinary ejaculation are observed.

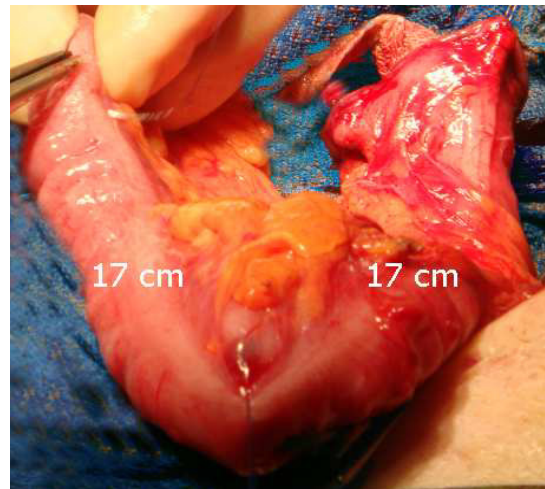
Figure (11): The ureter is identified, dissected till arterial capillary bleeding and stented.



- Selection of the colon segment depends on the descending colon is required to create a pouch of adequate capacity (400–600 ml).
- The right or left colic flexure should be mobilized completely to gain adequate colon length for the pouch.
- The greater omentum is separated from the transverse colon from right to left in the TAP and left to right in the TDP.
- The blood supply of the colon, which has some anatomical variability, is identified by transillumination. 2x17 cm of the colon is then resected between stay sutures (Figure 12).

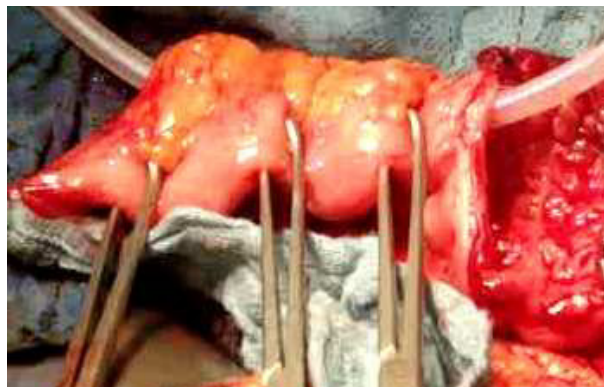

Figure (12): 2x 17 cm of the transverse-ascending or the transverse –descending colon is selected.



- Colo-colostomy is performed with interrupted seromuscular sutures (4×0 monofilament material). The colon is detubularized antimesenterically leaving 5–6 cm of the oral or aboral end intact for creating the efferent segment this segment is tapered over an 18 F silicone catheter (Figure 13).

Figure (13): The efferent segment is tapered over an 18 F silicone catheter.

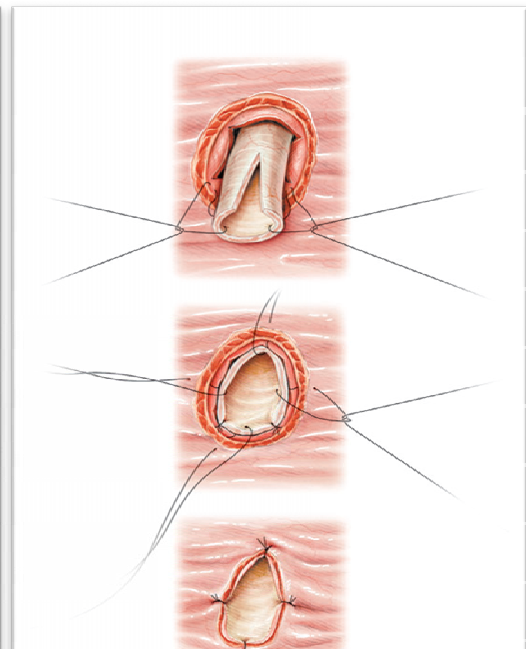


- The pouch plate is created using a running 4/0 monofilament polyglycol suture on a straight needle (Figure 14).
- The ureter can be implanted with an antirefluxing or refluxing technique.
- For the antirefluxing uretero-intestinal anastomosis: A submucosal tunnel of  $\approx$  2 cm on both sides of the suture link is created between stay sutures. The ureters are pulled through the tunnel and a neo-ostium is made with 5×0 absorbable sutures. The ureteric adventitia is fixed at the external pouch wall with two 5.0 sutures (Thüroff et al. 1986).

- 

plate is created using  
rofilament polyglycol  
needle. (From BJU Int.  
0.Colonic pouch (Mainz-  
nary diversion. Leissner J,  
Illustration by STEPHAN  
stration.com)

ie pull-through  
Int. 2006 Feb; 97  
(Mainz-pouch III) for  
Leissner J, Fisch M,  
tion by STEPHAN  
stration.com)



rtight anastomosis  
m BJU Int. 2006 Feb;  
uch (Mainz-pouch III)  
sion. Leissner J, Fisch  
stration by STEPHAN  
istration.com)

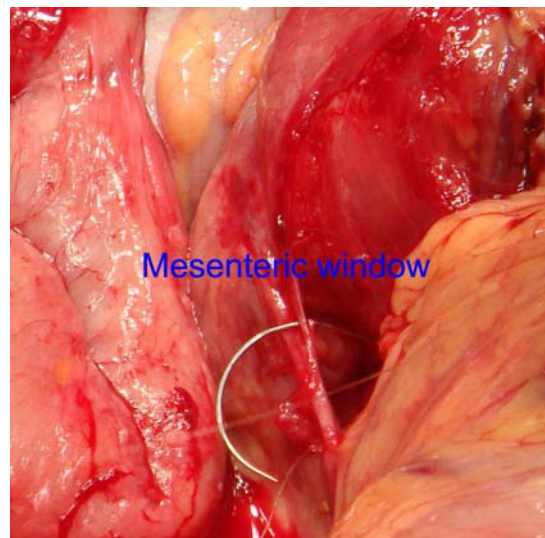


The 6 or 8 F smooth ureteric stents are placed and fixed. Along with a 10 F pouchostomy, the ureteric stents are led out through the pouch and abdominal wall at separate sites (Figure 18).

The pouch is closed and the efferent segment embedded in the anterior suture line of the pouch wall (Figure 19).

- Windows are dissected in the mesentery of the tapered colon between the vessels.
- The efferent segment is then placed in the suture line and the seromuscular layer of the anterior wall sutured together through the mesenteric windows using nonabsorbable sutures.
- The anastomosis between the umbilical funnel and the efferent segment is made at the level of the rectus fascia and the pouch fixed to the abdominal wall.
- The pouch is fixed at the anterior and lateral abdominal wall with interrupted sutures.

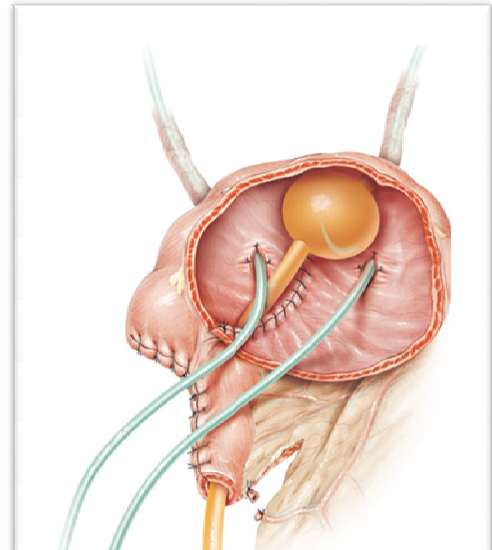
Figure (17): The mesenteric window is closed to avoid development of hernia through it.



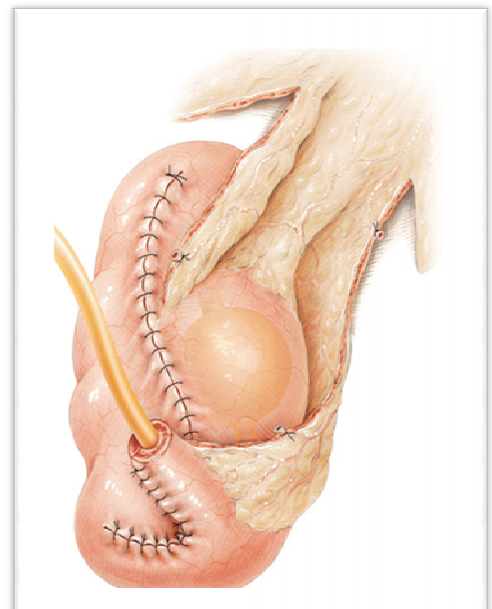
- The omentum is used as a flap to cover the pouch and the bowel. As it is recently reported the advantages of a refluxing uretero-intestinal anastomosis, with almost no risk of ureteric obstruction and subsequent deterioration in kidney function, this is the technique of choice in adults. The antirefluxing implantation technique should only be used in children (Hohenfellner et al. 2002).

As large bowel surgery is less common than small bowel procedures in most urological centers, the following points may be helpful for avoiding problems during and after surgery:

- Because of the greater mobility of the large bowel than the small bowel, only minimal separation (4–5 cm) of the mesentery is necessary. The blood supply is thus less at risk.
  - Open resection without clamps or staplers makes capillary bleeding recognisable, which is important in irradiated bowel surgery with significant vascular damage.
  - Macroscopically, irradiated bowel looks smaller and is contracted, less vascularized, and sometimes pale with fibrotic adhesions, and especially in the ileocaecal region, may be fixed to the abdominal wall. In addition, palpation of the wall thickness is important to identify the line of resection.
  - A minimum safety margin of 5–7 cm should be left, so that large bowel continuity can be restored later.
  - 4–0 polyglycol interrupted sutures through the seromuscular layer are used for end-to-end-anastomosis.
  - To feel safer, a semicircular running suture of the mucosa can also be added.
- Although our experience with the efferent segment is excellent (Leissner et al. 2000).



ne 6 or 8 F smooth  
s are placed and  
g with a 10 F  
From BJU Int. 2006 Feb;  
onic pouch (Mainz-pouch  
rinary diversion. Leissner  
nfellner R. Illustration by  
ITZER, www.spitzer-



The pouch is closed.  
2006 Feb; 97 (2):417-  
h (Mainz-pouch III) for  
y diversion. Leissner J,  
nfellner R. Illustration by  
PITZER, www.spitzer-

Figure (20): The pouch after closure.

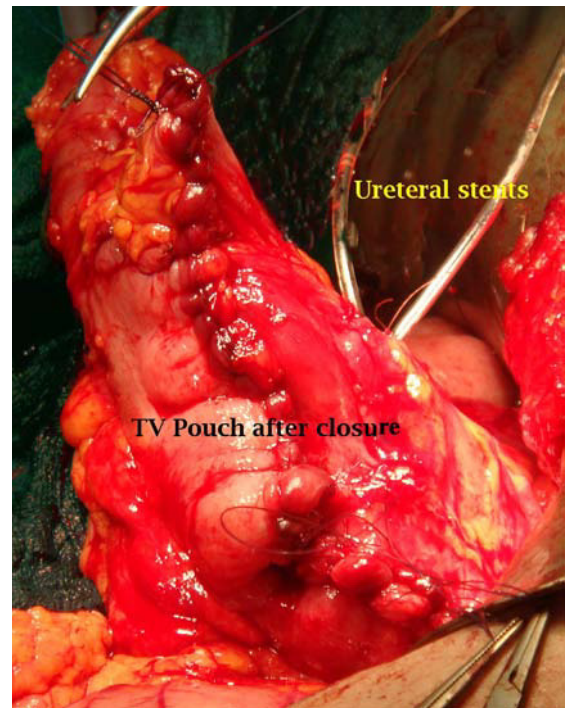
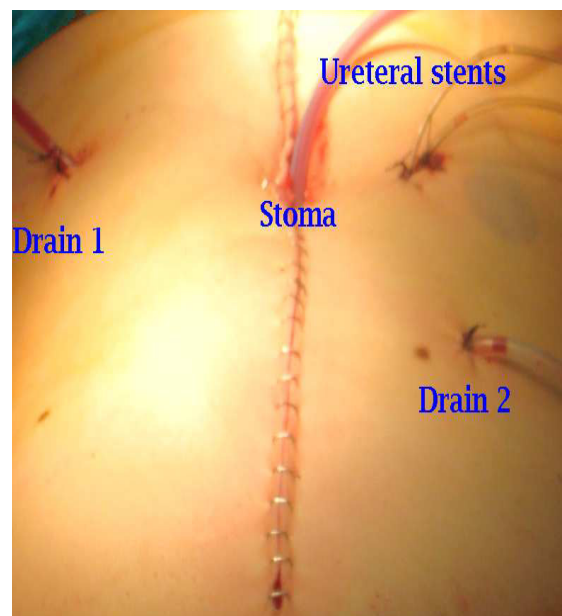


Figure (21): Drains, ureteral stents and pouch catheter at the end of the operation.



#### 4.9. Transverse colon conduit (Hohenfellner and Fisch 2004).

##### 4.9.1. Preoperative preparation

Preoperatively an intravenous urography (IVU) should be performed to evaluate the upper urinary tract. An enema with water-soluble contrast medium should be done to exclude diverticula or polyps.

The bowel is irrigated with Ringer's lactate solution (8 to 10 L) via a gastric tube or oral intake of 5 to 7 L of Fordtran's solution. The day before surgery, positioning of the stoma should be done.

The best position is in the epigastric region; the attached stoma plate has to be checked in sitting, lying, and standing positions of the patient.

##### 4.9.2. Surgical technique

###### A) Instruments required

Include a basic kidney set with additional instruments for intra-abdominal surgery, Siegel's retractor, suction, and a basin containing prepared iodine solution for disinfection.

###### b) Suture material

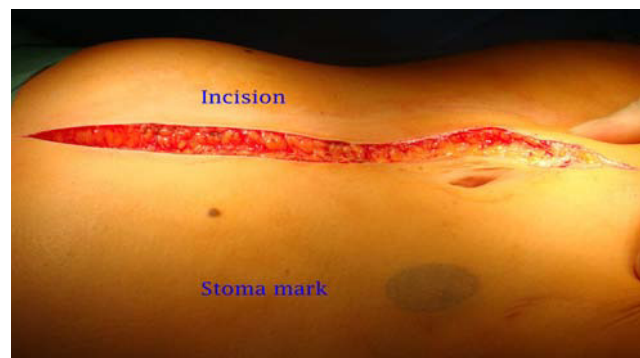Absorbable monofilament sutures like polyglycolic acid 4-0 are used for closure of the conduit and intestinal anastomosis to reestablish bowel continuity as well as creation of the stoma.

###### c) Surgical steps

Access is gained by median laparotomy.

Both ureters are identified at the crossing over the iliac vessels and dissected in the cranial direction. The dissection toward the bladder goes down until the irradiated level is reached. The ureters are cut above the irradiated field, where they show good vascularization. There should be capillary arterial bleeding out of the ureteral wall and spontaneous urine efflux.

Figure (22): skin incision and the predetermined stoma mark.



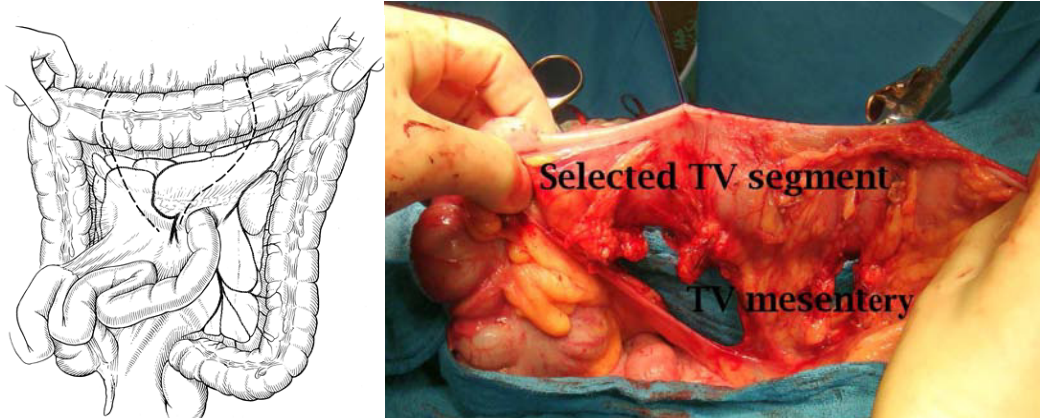
The ureteral stump is ligated and the cranial end is marked by a stay suture. Depending on the remaining length of the ureters it is decided, which one can be brought to the opposite side by a retromesenteric pull-through. The retromesenteric entrance should be wide enough and the path of the ureter slightly curved in order not to angle or compresses it.

A bowel segment of approximately 15 cm in length in patients with normal weight is selected respecting the course of the vessels. The length of the segment depends on the thickness of abdominal wall.

Stay sutures outline the segment.

Bowel mobilization differs depending on the segment chosen: If the ascending segment is selected the right colonic flexure is mobilized. The greater omentum is separated from the transverse colon over a distance of 10 to 15 cm starting at the right side. When the descending colon is chosen, the left colonic flexure has to be mobilized and the left part of the omentum has to be separated from the transverse colon.

The selection of a transverse colonic segment makes mobilization of both the right and left flexure necessary as well as a complete separation of the greater omentum from the transverse colon.



*Figure (23): A bowel segment of approximately 15 cm in length in patients with normal weight is selected respecting the course of the vessels.*

The mesentery of the selected segment is incised lateral to the supplying artery and the arcade is divided between mosquito clamps and ligated.

The fat is dissected from the seromuscularis of the bowel in the area where the segment will be cut and bleeding vessels are coagulated.

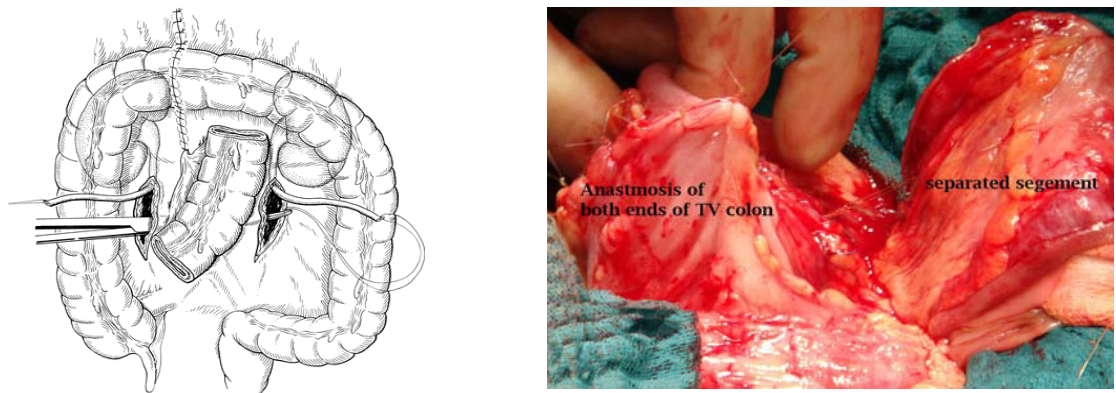


The segment is isolated without the use of clamps so that the bleeding out of the ends can be seen. The segment is cleaned using moist sponges.

Bowel continuity is reestablished by a one-layer seromuscular suture using polyglycolic acid 4-0 and the mesenteric slit is closed by running suture.

One option for ureteral reimplantation uses the Wallace technique (Wallace 1970). Both ureters are resected to an adequate length and spatulated over a distance of 3 cm. A stay suture is placed at the 6-o'clock position and a ureteral stent inserted. The first suture for anastomosis of the medial margins of the ureters is placed at the 12-o'clock position and tied later.

The anastomosis is performed by a running suture polyglycolic acid 5-0.

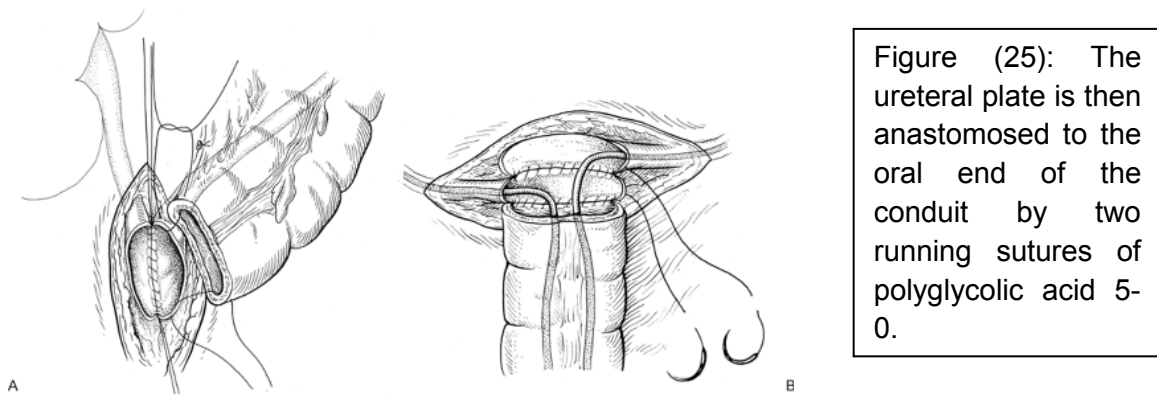

*Figure (24): Bowel continuity is reestablished by a one-layer seromuscular suture using polyglycolic acid 4-0 and the mesenteric slit is closed by running suture.*

The ureteral stents are fixed to the ureteral mucosa (polyglactin 4-0 with short reabsorption time) and subsequently brought out through the conduit.

The ureteral plate is then anastomosed to the oral end of the conduit by two running sutures of polyglycolic acid 5-0.

When the conduit is positioned on the right side and the left ureter is relatively short, it can be implanted to the right ureter.



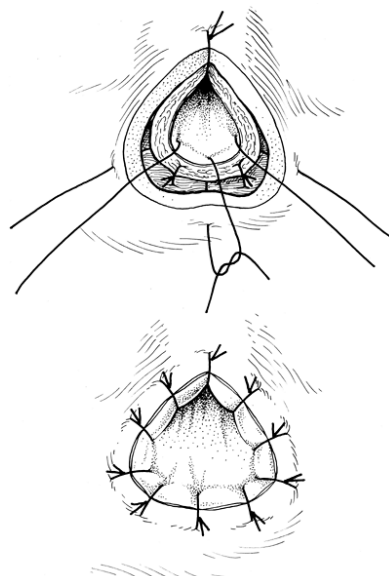
**Figure (25):** The ureteral plate is then anastomosed to the oral end of the conduit by two running sutures of polyglycolic acid 5-0.

An alternative method of ureteral reimplantation is a direct implantation using a buttonhole technique.

The conduit is longitudinally opened in the area of the taenia libera over a length of 3 to 4 cm starting at the oral end. Two stay sutures are placed at the back wall of the conduit.

The mucosa in between is excised and the seromuscular layer incised to create an entrance for the ureter. The ureter is pulled through and implanted by two anchor sutures at the 5- and 7-o'clock positions (polyglycolic acid 4-0) and mucomucous sutures (polyglycolic acid 5-0).

A stent is inserted, fixed, and led out through the conduit. The contralateral ureter is implanted in the same manner and the conduit closed.



*Figure (26a): The mucosa in between is excised and the seromuscular layer incised to create an entrance for the ureter.*

The preferred method for antirefluxive ureteral implantation is the Goodwin technique (Goodwin 1953).

The conduit is longitudinally opened over a length of approx. 4 cm starting from the end chosen for ureteral implantation (proximal end preferable). Four stay sutures are placed to facilitate ureteral implantation.

A submucosal tunnel is dissected starting from the end of the conduit (tunnel length, 3 to 4 cm). The bowel mucosa at the end of the tunnel is incised and the ureter is pulled through the respective submucosal tunnel.

After spatulation and resection of the ureter to an adequate length, implantation is performed by one anchor suture at the 6-o'clock position,

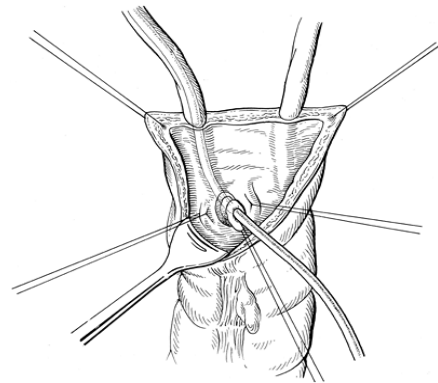
grasping the seromuscularis of the bowel and all layers of the ureter (polyglycolic acid 5-0). The anastomosis is completed by mucomucous single sutures (polyglycolic acid 6-0).

To secure the ureteral implantation a 6 Fr ureteral stent is inserted in each ureter and fixed to the bowel mucosa (polyglactin 4-0 with short reabsorption time).

For implantation of the second ureter a second tunnel is prepared beside and parallel to the first; the implantation is done in the same way.

Both ureteral stents are led out through the aboral end of the conduit. The proximal end of the conduit and of the incision line in the area of the taenia libera are closed (single seromuscular sutures, polyglyconic acid 4-0).

Figure (26b): For implantation of the second ureter a second tunnel is prepared beside and parallel to the first; the implantation is done in the same way.

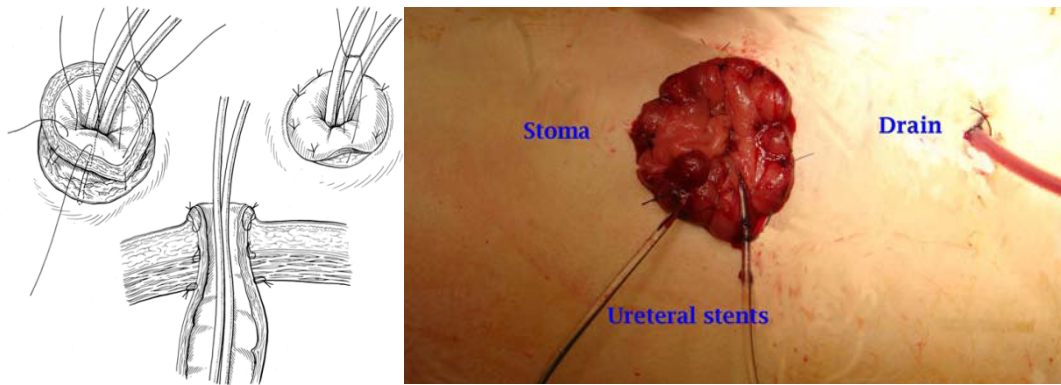


A circular area of the skin (approx. 3 cm in diameter) is excised.

The abdominal fascia is crosslike incised and the conduit is pulled through the fascial and the skin opening together with the ureteral stents by means of two Allis clamps after having freed the distal end of the conduit of fat and epiploic appendices.

The seromuscularis of the conduit is fixed to the abdominal fascia by circular single stitches of polyglycolic acid 3-0 and the oral end of the conduit is anastomosed to the skin by circular single stitches of polyglycolic acid 5-0 everting the stoma.





*Figure (27): The seromuscularis of the conduit is fixed to the abdominal fascia by circular single stitches of polyglycolic acid 3-0 and the oral end of the conduit is anastomosed to the skin by circular single stitches of polyglycolic acid 5-0 everting the stoma.*

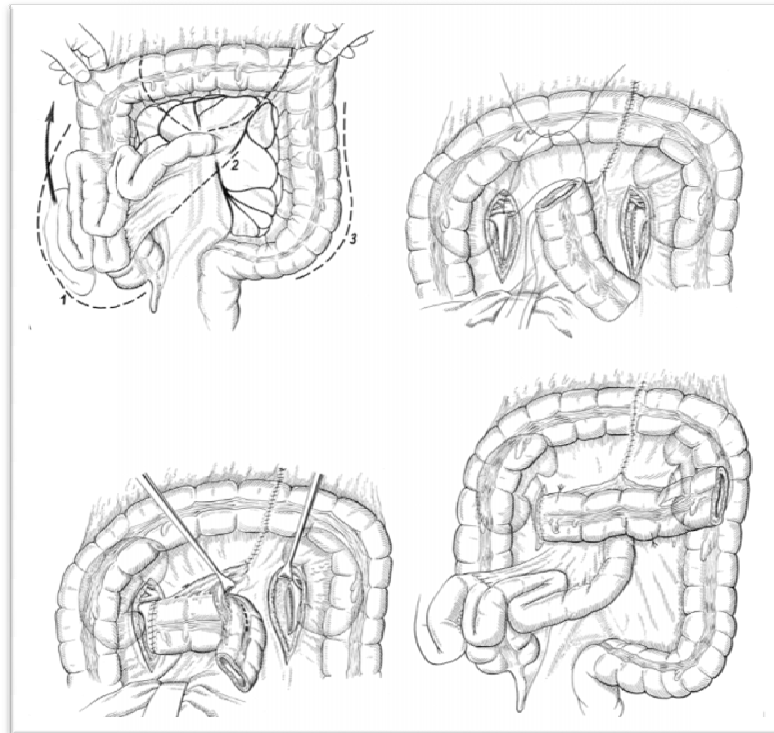
#### **d) Pyelotransverse Pyelocutaneostomy**

An extensive bowel mobilization is necessary including caecum, root of the mesentry, Treitz's ligament, and the right and left colonic flexures. The omentum majus is completely dissected from the transverse colon and the bursa omentalis is opened.

The bowel is exteriorized out of the abdomen. The ureters are cut at the ureteropelvic junction and the renal pelvis is longitudinally spatulated. A transverse colon segment with a length of 25 to 30 cm and an adequate blood supply is isolated. After having placed a ureteral stent in a calyx of the right kidney and fixed the stent inside the renal pelvis (polyglactin 4-0 with short reabsorption time) an end-to-end anastomosis of the right renal pelvis and the distal end of the conduit is performed using two running sutures of polyglycolic acid 5-0.

The ureteral stent is led out through the conduit before the anastomosis is completed. The conduit is brought to the left renal pelvis without tension. Also on this side, a stent is inserted into the kidney, fixed, and led out through the conduit later.

For anastomosis of the renal pelvis with the conduit, the wall of the conduit is incised at the taenia libera over an adequate length and an end-to-side anastomosis of the renal pelvis and the conduit done by two running sutures of polyglycolic acid 5-0. The stoma formation is identical to the standard technique.



*Figure (28): An extensive bowel mobilization is necessary including caecum, root of the mesentery, Treitz's ligament, and the right and left colonic flexures.*

#### **e) Surgical Tips**

*Transilluminating the mesentery by a fiberoptic light source visualizes the vessels and facilitates the selection of the segment as well as the preparation of the mesenteric slits.*

*When the conduit is positioned on the right side and the left ureter is relatively short, it can be implanted directly to the right ureter (like the crossed hands of a ballerina). This is applicable for the Goodwin and Hohenfellner as well as the Wallace technique.*

*The colonic conduit can be performed so that the urine flow is peristaltic and antiperistaltic so that the stoma can be alternatively positioned in the right or left upper-abdominal quadrant.*

*For an antiperistaltic application, an extensive mobilization of Treitz's ligament and the descending part of the duodenum becomes necessary; otherwise, compression of the duodenum by the conduit may result.*

*An extraperitonealization of the conduit facilitates revisional surgery, as this can be done through a flank incision. Thereby, a transabdominal approach with the need for adhesiolysis can be avoided.*

#### 4.9.3. Postoperative care

Antibiotics are given for 5 days.

Parenteral nutrition is continued until bowel contractions appear and then gradually reduced. The gastric tube is removed starting from postoperative day 3 after clamping. The rectal tube stays for 3 days.

Ureteral stents are loosened after day 9 and removed after day 10, beginning on one side with a check of the kidney by ultrasonography on day 11. Then, the second stent is removed.

An IV urography demonstrates regular kidney function after stent removal.

The acid-base balance should be checked before the patient is discharged.

The patient should be taught about all aspects of stoma care.

#### 4.10 Follow up

Follow up visits are scheduled every month for half a year and then every 2 months thereafter. Evaluation of the patients includes:

a) History and clinical examination (each visit):

- Analysis of the symptoms.
- Clinical examination for features of dehydration, renal failure or acidosis.
- Examination of abdominal stoma at rest and stress and calibration of the continent outlet.
- Rectal examination to detect local pelvic recurrence.

b) Laboratory evaluation:

Urine culture, serum creatinine and serum electrolytes (K and Na) are performed every 6 months, acid base profile is obtained for all patients.

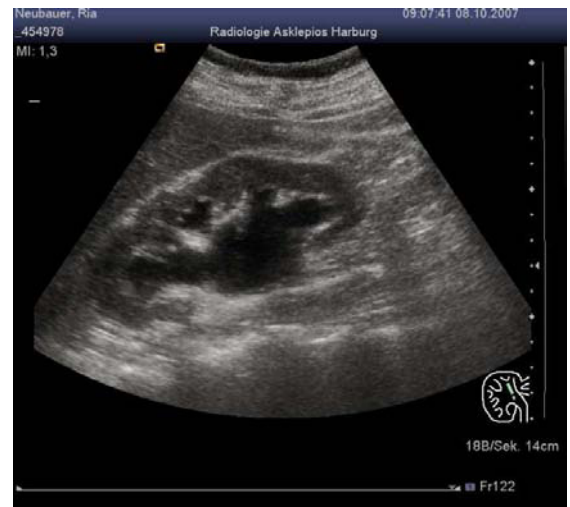

Figure (29): Follow-up ultrasound showing hydronephrosis.

c) Radiological evaluation

1- Abdominal ultrasound:

Routinely done in all patients each visit to detect size and echogenicity of the kidney upper tract dilatation and pyelonephritic changes.

2- Intravenous urogram (IVU):

Obtained routinely at 6 months post operatively and may be later if renal

sonographic configuration is questionable in

documenting the radiographic anatomy of the upper tract.

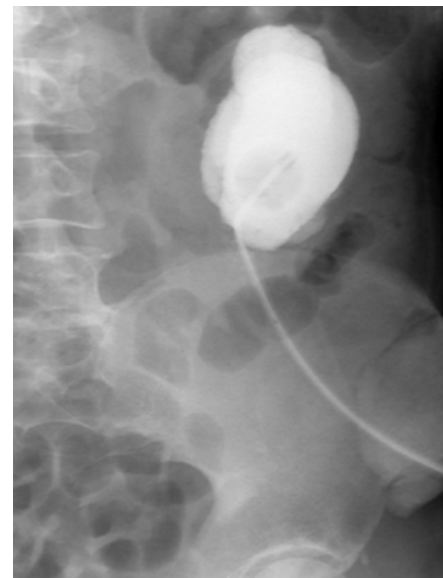

Figure (30): Ascending pouchogram.

d) Ascending pouchography:

Carried out 6 months after surgery to assess the configuration and capacity of the pouch, efficiency of the reflux preventing system as well as the continence mechanism. Post catheterization radiographs are obtained to verify the adequacy of the reservoir emptying following catheterization.

e) Other studies:

Computerized tomography, urodynamic evaluation, magnetic resonance imaging and bone scan were performed as clinically indicated.

#### 4.11. Data collection

**Data of this study was collected through the following methods** *(After taking consent from the included patients):*

- Review the hospital documentations: including the operative reports and reports of follow up and results of investigations either preoperative or post operative.
- Direct contact with the patients through the follow-up visits.
- Sending the following questionnaire to all patients *(in German language)*.

#### 4.11.1. The Questionnaire (non validated)

Dear miss/sir:-

.....  
Because of scientific research about transverse colon pouch we need your answer about the following questions:

**Have you received radiotherapy before?**

-Yes -No

*When yes how much (Gray)?*

-32 Gy

-48 Gy

-60 Gy

-other (.....) Gy

**What is the latest date of follow up?**

.....  
**Do you know the latest creatinin level?**

.....  
**Do you know the latest blood tests:**

-PH

.....  
-Sodium

.....  
-Potassium

.....  
-Chloride

.....  
**Do you know the latest pouch capacity?**

- 100-200 ml
- 200-300 ml
- 300-400 ml
- 400-500 ml
- < 100 ml
- Other.....ml

**Did you have any operations after the transverse colon pouch?**

-Yes -no

*When yes which operation? Why?*

.....  
.....  
.....

1. Stone formation
2. Failure of catheterization
3. Incontinence
4. Parastomal hernia
5. Diltation of one or both of kidneys
6. Recurrent urinary tract infection
7. Others.....

- More as every 2 hours
- Every 2-3 hours
- Every 3-4 hours
- Less than every 4 hours
- 

- More than 4times
- 2-4 Times
- 1-2 Times

-yes                      -no

	Yes	No
	Highly satisfied (+++)	Mildly satisfied (-)
	Moderately satisfied (++)	Moderately satisfied (--)
	Mildly satisfied (+)	Highly satisfied (---)

-Yes -no

-Yes -no

-Yes -no

**Does it cause any residual discomfort related to urinary diversion?**

**-Yes**

**-no**

**Would you like to add another information or comment?**

.....

.....

.....

.....

**Note:** *The same questionnaire with some modifications was sent to patients of transverse colon conduit.*

#### 4.11.1. Der Fragebogen

Sehr geehrte Patientin, sehr geehrter Patient,

Bei Ihnen wurde an unserer Klinik eine offene Operation zum Blasenersatz (Pouch) durchgeführt. Da dies eine Methode ist, die nur an wenigen Kliniken und selten durchgeführt wird ist es für uns sehr wichtig, den weiteren Verlauf zu untersuchen.

Hierfür bitten wir Sie um Ihre Mithilfe. Ziel ist es, Methoden und Operationsverfahren zu verbessern. Dafür bitten wir Sie, beiliegenden Fragebogen möglichst sorgfältig zu beantworten. Sollten Sie eine Frage nicht beantworten können, gehen Sie einfach zur nächsten Frage über.

Selbstverständlich werden Ihre Angaben vertraulich behandelt und anonym ausgewertet.

Herzlichen Dank für Ihre Mithilfe!

Wir bitten Sie, den fertigen Fragebogen im beiliegenden, vorfrankierten Kuvert möglichst innerhalb der nächsten Tage an unsere Abteilung zurückzusenden. (**weil wir jetzt in Klinik und Poliklinik für Urologie, Universität Klinikum Hamburg-Eppendorf arbeiten, bitten wir Sie Ihre Antwort an unsere neue Adresse zurücksenden**)

Mit freundlichen Grüßen

Das urologische Team der Asklepios Klinik Harburg

Prof. Dr. M. Fisch  
Chefärztin

Khalid Sayedahmed  
Gastarzt



**Bitte beantworten Sie die folgenden Fragen:**

1. Wenn eine Bestrahlung durchgeführt wurde: wissen Sie, wie viel Gray verwendet wurden?

- ☐ ja ☐ nein

Wenn „ja“, wieviel?

- ☐ 32 Gray  
☐ 48 Gray  
☐ 60 Gray  
☐ anderes: ..... Gray

2. Wann fand die letzte Nachuntersuchung des Pouches statt?

.....

3. Kennen Sie Ihren letzten Kreatininwert? .....

4. Kennen Sie die Ergebnisse der letzten Blutuntersuchung für folgende Werte (bitte eintragen)?

pH-Wert: .....

Natrium: .....

Kalium: .....

Chlorid: .....

Base Exzess (BE): .....

5. Wissen Sie, wie viel etwa in den Pouch hineinpasst? (Größe Menge, die Sie in letzter Zeit katheterisiert haben.)

- ☐ weniger als 100ml  
☐ 100-200ml  
☐ 200-300ml  
☐ 300-400ml  
☐ 400-500ml

☐ anderes: .....ml

Wurden nach der Pouchoperation weitere Operationen durchgeführt?

☐ ja ☐ nein

Wenn „ja“, welche Art der Operation und warum? .....

.....

6. Trat bei Ihnen eine der folgenden Komplikationen auf?

- ☐ Pouchstein
- ☐ Katheterisierungsprobleme
- ☐ Inkontinenz
- ☐ Bauchwandbruch (Hernie)
- ☐ Nierenaufweitung oder –stauung
- ☐ Nierenbeckenentzündung
- ☐ andere:

.....

**Wenn ja, wie wurden sie behandelt?**

7. Wie häufig Katheterisieren Sie den Pouch am Tag?

- ☐ häufiger als alle 2 Stunden
- ☐ alle 2-3 Stunden
- ☐ alle 3-4 Stunden
- ☐ seltener als alle 4 Stunden

8. Wie häufig Katheterisieren Sie den Pouch in der Nacht?

- ☐ häufiger als 4 X
- ☐ 2-4 X
- ☐ 1-2 X

9. Benötigen Sie Sicherheitsvorlagen?

☐ ja ☐ nein

Wenn „ja“, wie viele?

☐ bis zu 2

☐ 2-10

☐ mehr als 10

10. Wie zufrieden sind Sie mit dem Ergebnis der Pouchoperation?

	Ja		Nein
	Sehr zufrieden (+++)		Leicht unzufrieden (-)
	Zufrieden (++)		Unzufrieden (--)
	Noch zufrieden (+)		Sehr unzufrieden (---)

Würden Sie diese Form der Operation noch einmal wählen?

☐ Ja

☐ Nein

Würden Sie diese Form der Operation anderen empfehlen?

☐ Ja

☐ Nein

Sind Sie zufrieden mit den Effekten der Operation?

☐ Ja

☐ Nein

Bestehen weiterhin Unannehmlichkeiten bezüglich Ihrer Harnableitung?

☐ Ja

☐ Nein

11. Falls Sie weitere Bemerkungen anfügen möchten, die in den oben genannten Fragen nicht erwähnt wurden bitten wir Sie, diese hier anzuführen:

## 5. Results

### 5.1. Age and sex distribution

In our study 43 cases were included; 23 cases with transverse colon pouch and 20 cases of transverse colon conduit. Cases are classified according to age and gender.

		Transverse colon pouch	Transverse colon conduit
Gender	Male	8	10
	Female	15	10
Age (in years)	Mean	45.5	50
	Range	19-72	19-81

Table (2) shows the gender and age distribution of the patients included in our study as the following:

Transverse colon pouch cases included 8 males (34.8%) and 15 females (65.2%). The age of the cases ranged from 19 to 72 years with the Mean age 45.5years. Transverse colon conduit cases included 10 males (50%) and 10 females (50%). The age of the cases ranged from 19-81 years with the mean age 50 years.

### 5.2. History of irradiation

78.3% of patients of transverse colon pouch had history of irradiation with the average dose of irradiation 46 Gray. 90% of patients of transverse colon conduit had history of irradiation with the mean irradiation dose 51.5 Gray

Table (3): History and dose of irradiation.

		Transverse colon pouch	Transverse colon conduit
History of irradiation	Positive	18	18
	Negative	5	2
Dose of irradiation (Gray)	Mean	46	51.5
	Range	32-60	37-66

### 5.3. Operative Evaluation

		Transverse colon pouch	Transverse colon conduit
Average operative time (hs)	Without cystectomy	4,8	4.2
	With cystectomy	6.8	5.9
Average blood loss (ml)		400	450
Operative complications %		-	10%

Table (4): The operative evaluation of the high urinary diversion in regard to the operative time, intraoperative blood loss and intraoperative complications.

Table 4 shows the following:

In transverse colon pouch cases the average operative time was 4.8 hours without cystectomy and 6.8 hours in cases with cystectomy , the average blood loss was 400 ml without operative complications. In transverse colon conduit cases the average operative time was 4.2 hours in cases without cystectomy and 5.9 hours in cases with cystectomy with the average blood loss 450 ml and intraoperative complications in 10% of cases in the form of excessive blood loss due to extensive adhesion. In all cases there was no major intraoperative complication e.g. organ injury.

### 5.4. Early postoperative evaluation

#### 5.4.1. Hospital stay

The average postoperative hospital stay was 16 days for patients with transverse colon pouch and 14 days in cases with transverse colon conduit.

#### 5.4.2. Early postoperative complications (before patient discharge from hospital) occurred in 3 patients (13%) with transverse colon pouch:

One patient had hydronephrosis managed by nephrostomy tube insertion, one patient had hypokalemia managed by oral potassium and one patient had wound infection managed by antibiotic according to the culture result.

**In patients with transverse conduit early postoperative complications occurred in 5 patients (25%):**

Two patients had anemia due to intraoperative blood loss managed by blood transfusion (each 2 units), one patient had electrolyte disturbance and acidosis.

Two patients had prolonged paralytic ileus.

Except of one case of hydronephrosis at one side all the early postoperative complications were minor and managed successfully.

## 5.5. Follow up

The average follow up of the patients included in our study was 52.2 months with the range of the follow up period 1-104 months.

### 5.5.1. Biochemical evaluation and complications during the follow up period:

Table (5) show the biochemical evaluation of the patients in regard to the serum Creatinine, Sodium, Potassium, Bicarbonate and PH. Serum Creatinine levels remained at the preoperative level in all patients. Therapy for metabolic acidosis was not required in all patients.

Table (5) Biochemical evaluation:

	Transvers colon pouch Mean $\pm$ SD	Transverse colon conduit Mean $\pm$ SD
Creatinine mg/dl	0.9 $\pm$ 0.2	0.8 $\pm$ 0.1
Na <sup>+</sup> meq/l	142 $\pm$ 2.6	141 $\pm$ 3.8
K <sup>+</sup> meq/l	4.4 $\pm$ 1.5	4.3 $\pm$ 1.8
HCO <sub>3</sub> meq/l	22 $\pm$ 2.1	23.1 $\pm$ 1.9
PH	7.38 $\pm$ 0.08	7.37 $\pm$ 0.02

Table (6): Complications during the follow up period.

	Transverse colon pouch	Transverse colon conduit
Stone formation	1(4.3%)	-
Failure of catheterisation	2(8.6%)	-
Nipple insufficiency	3(13%)	-
Hydronephrosis	3(13%)	1(5%)
Ureteral stricture	1(4.3%)	-
Deterioration of renal function	-	-
Electrolyte disturbance	2(8.6%)	1(5%)

Recent urinary tract infection	1(4.3)	2(10%)
Parastomal hernia	-	-
Diarrhea	-	-
Outlet -stenosis	2(8.6%)	-
Bone symptoms	-	-

There were 3 cases of nipple insufficiency managed by nipple revision, one case of stone formation in the pouch managed by endoscopic fragmentation and extraction (Figure 32), two cases of outlet stenosis that required revision; correction of the efferent limb had to be combined with revision of the stoma, a second revision was needed and the urinary diversion was converted to a conduit, 4 non-symptomatic upper urinary tract dilatation 3 months after surgery and one case of ureteral stricture needed insertion of nephrostomy tube (Figure 32). There was no diarrhea related to the urinary diversion. There were no bone symptoms or pathological fractures.

## 5.6. In regard to the transverse colon pouch:

### 5.6.1. Pouch capacity

Of the 23 patients with transverse colon pouch; 14 patients (60.9%) had pouch capacity ranged from 300 to 400 ml; 6 Patients (26.1%) had pouch capacity less than 200 ml and 3 (13.4%) patients had pouch capacity more than 500 ml. Most of the patients with small pouch capacity were in the 1<sup>st</sup> postoperative year. The mean pouch capacity was 297.4 ml.

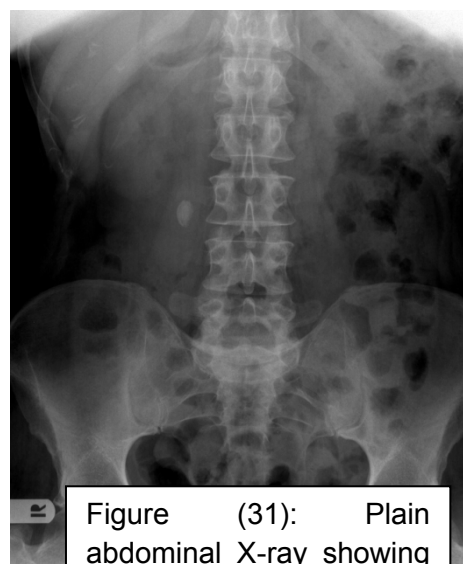


Figure (31): Plain abdominal X-ray showing pouch-stone.

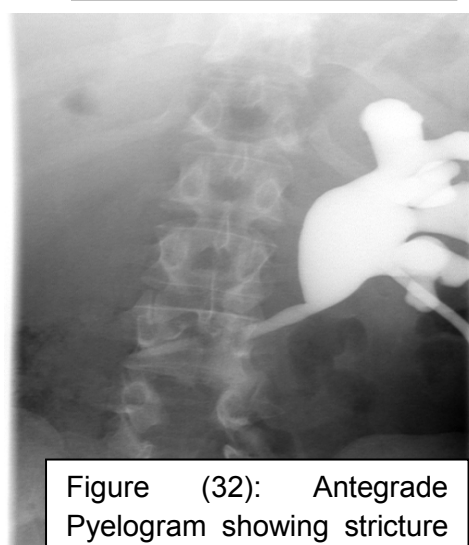


Figure (32): Antegrade Pyelogram showing stricture at uretero-pouch anastomosis.

### 5.6.2. Continence

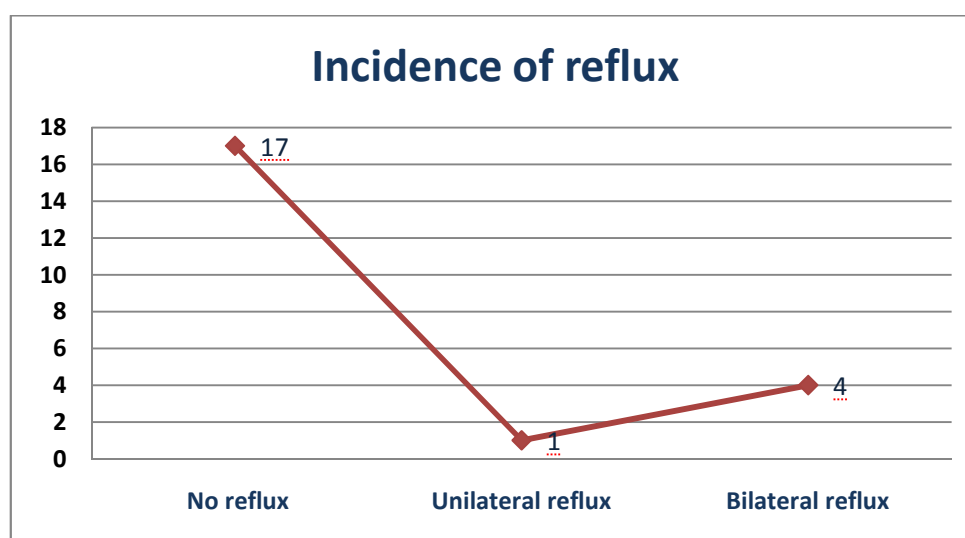
Of 23 patients with transverse colon pouch 19 patients (82.6%) were fully continent during follow up period and 4 patients (17.4%) required security pads. All patients used self catheterization with the frequency of catheterization 4-6 at day time and 1-3 at night.

### 5.6.3. Poucho-ureteral reflux

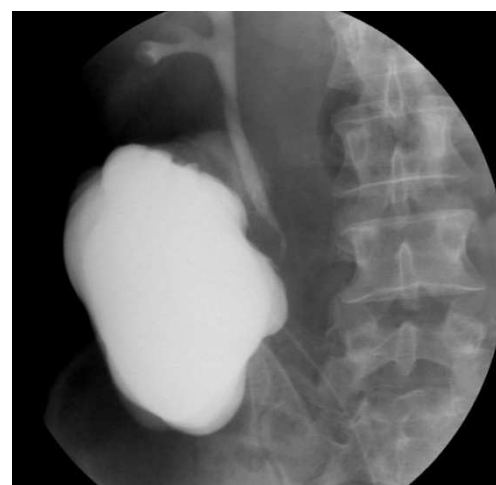

Figure (33): Pouchogram showing poucho-ureteral reflux

Diagram (a): Incidence of reflux.



Postoperative pouchograms revealed reflux in 4 patients (filling volume > 300 ml). Although direct ureterointestinal anastomosis without antireflux implantation is used in all cases of transverse colon conduit also in all cases of transverse colon pouch, there were only 5 cases (21.7% of cases of transverse colon pouch) of reflux with no consequences, despite using a refluxing implantation technique (Figure 34, 35). Even at long-term follow up no deterioration in kidney function was observed and there was no recurrent obstruction. Although routine scintigraphy was not performed, normal serum creatinine, absent kidney dilatation and stable renal parenchymal thickness on sonography are important and certain signs of stable kidney function.



### 5.7. Quality of life

A short form Quality of life questionnaire adopted for brief estimation of patients satisfaction with the transverse colon diversion.

The questionnaire was done partially by person to person contact, partially by sending a letter to the patients.

The questionnaire involved the following questions:

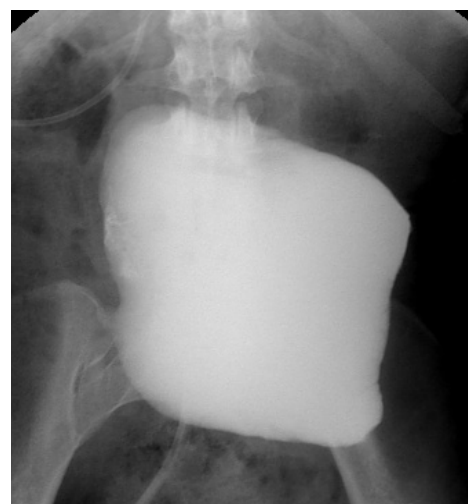


Figure (34): Pouchogram showing no reflux inspite of using direct implantation technique.

1-Are you satisfied from this procedure? Please choose the answer.

Table (7): Degree of satisfaction

	Yes		No
	Highly satisfied (+++)		Mildly unsatisfied (-)
	Satisfied (++)		Moderately unsatisfied (--)
	Mildly satisfied (+)		Highly unsatisfied (---)

2-Would you choose the same procedure again?

3-Would you recommend the procedure to others?

4- Are you content with the effects of this procedure?

5-Does it cause any residual discomfort related to urinary diversion?

**For question No 1:** The answer of the patients showed that from the patients of transverse colon pouch; 60.8% are highly satisfied from the operation; 17.4% are satisfied; 8.7% are mildly satisfied; 8.7% are mildly unsatisfied and 4.3% are moderately unsatisfied. From patients with transverse colon conduit; 60% are highly satisfied from the operation; 25% are satisfied; 10% are mildly satisfied and 0.5% are mildly unsatisfied.

**For question no 2:** 97.7% of patients responded that they would choose the procedure again.

**For the question no.3:** 95.3% of the patients responded that they would recommend the procedure to the others with the same indication.

**For the question no. 4:** 97.7% of the patients responded that they are content with the effects of the procedure.

**For the question no. 5:** 88.2% of patients responded that they have no residual discomfort related to the urinary diversion.

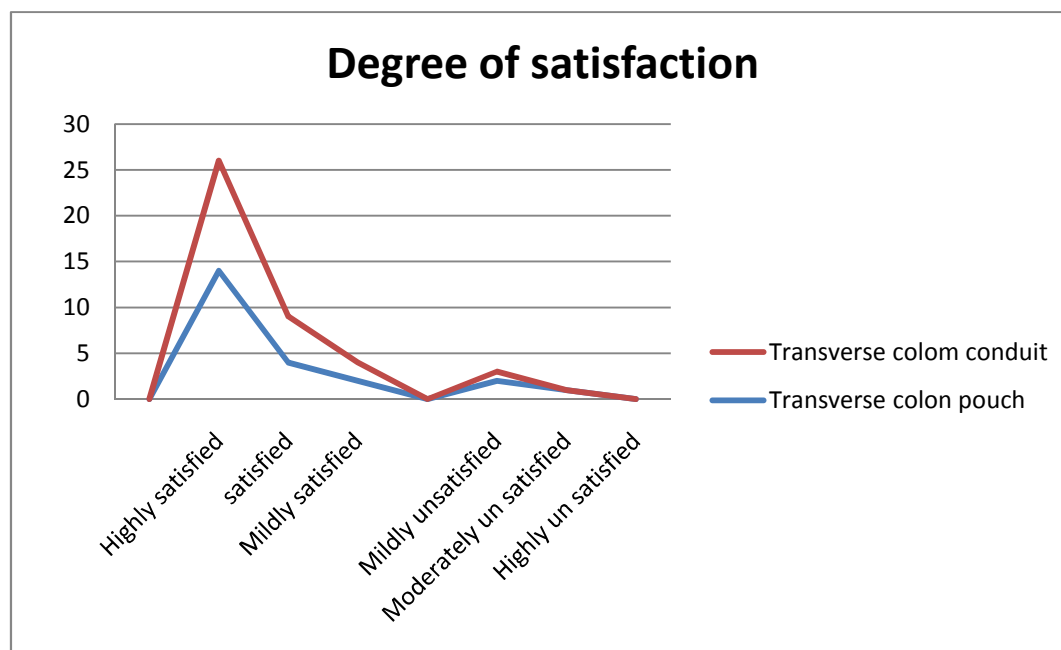


Diagram (b): Degree of satisfaction.

## 5.8. Death during Follow up

Nine patients (20.9%) died during the follow-up; 4 patient with transverse colon pouch and 5 patients with transverse colon conduit. The cause of death was disease progression in 6 patients (13.9%), myocardial infarction in one patient (2.3%), one patient (2.3%) committed suicide for reason unrelated to the urinary diversion and one patient (2.3%) had sudden death (the cause was not mentioned).

## 6. Discussion

### 6.1. Indications

Radiotherapy is well established in the therapy of advanced cervical and endometrial cancer and local recurrence. The high-radiation dose necessitated by the poor radiation sensitivity of the vagina and cervix leads to early or late complications (Jordan et al. 1987, Eifel et al. 1995, Haie-Meder et al. 1994, Perez et al. 1999, Magrina 1993 and Zoubeket al. 1989). The complication rate increases if radical surgery is also performed (Weems et al. 1985). The most severe urologic complications are vesicovaginal or cloacal fistulas and bilateral ureteral stenosis. Reconstructive surgery in the previously irradiated area is difficult and often unsuccessful. After failed reconstructive surgery or in irreparable fistulas, urinary diversion is indicated, sometimes in combination with a colostomy (Bissada 1985). Considering the high prevalence of cervical carcinoma and wide use of radiation therapy, the management of the vesicovaginal fistula becomes an important issue for modern female urology. Management of radiation-induced vesicovaginal fistula is a complex issue, which demands time and major efforts from both medical personnel and patients. Most of the institutions prefer to perform urinary diversion instead of repairing a radiated fistula, because the surgical procedures are usually complex and with low success rates (Boronow et al. 1986 and Zoubek et al. 1989).

Since every fistula is unique and requires an individualized approach, it is difficult to describe a standard fistula repair, but some useful tips and general principles can be summarized. First, surgery should be avoided until an acute postradiation tissue response is progressing. A fistula occurring in a radiated field should be periodically reassessed, given the propensity of these lesions to evolve over time. The minimal timing prior to repair approximates 12 months since the fistula first appeared. Lack of tissue, which can be mobilized, is the main problem the surgeon faces during radiation-induced fistula repair. If this is the case, one should use flap techniques in order to create a “waterproof” closure (Chapple et al. 2005). The success rate of radiation-induced vesicovaginal fistula repairs is between 40 and 100%. Only few case series with limited number of cases have been reported in the

literature. Most of the institutions prefer to perform urinary diversion instead of repairing a radiation fistula, because the surgical procedures are usually complex and with low success rates (Zoubek et al. 1989).

Urinary diversion should be considered in patients with malignant disease and residual tumour, especially if the patient is old and in poor general condition. Furthermore, it is recommended to do a urinary diversion in patients previously subjected to radiation therapy, and in patients on whom multiple attempts to close the fistula have been unsuccessful (Niels et al. 1999). Continent urinary diversions have become a feasible alternative to ileal and colonic conduits for patients undergoing radical pelvic surgery for gynecologic malignancies. Another indication for urinary diversion in previously irradiated patients is local tumor recurrence requiring anterior or total exenteration (Höckel 1995). To treat such patients, the urologist works with a team of gynecologists, rectal surgeons, and radiologists. Pelvic exenteration (PE) remains the only potentially curative treatment for selected nonmetastatic patients with advanced or locally recurrent gynecologic malignancies. When anterior or total PE is performed, an urinary diversion (UD) is required. An ideal UD should protect renal function, preserve body image and quality of life in women. After anterior or total PE for gynecologic malignancies, orthotopic ileal neobladder is not recommended because of: (a) the extent of the PE procedure to anterior vaginal wall, urethra, pubo-urethral ligaments, and endopelvic fascia that have to be spared when orthotopic neobladder is planned in women (Stenz et al. 2001); (b) the increased risk of urinary fistula (leakage of urethra-neobladder anastomosis) after prior pelvic radiation therapy; (c) the high local recurrence rate of gynecologic malignancies. Internal urinary diversion (ureterosigmoidostomy) is feasible but a high complication rate including recurrent pyelonephritis, ureteral stricture, and associated carcinoma of sigmoid has been reported (Leadbetter et al. 1996 and Mottaz et al. 1979). Moreover, after PE, sigmoid or rectum is not always usable and anal sphincter function could be impaired. Thus, heterotopic pouch is the main alternative to ileal conduit (Verhoogen et al. 1908). To maximize quality of life, gastrocystoplasty is an alternative solution for urinary diversion and can be indicated for irradiated patients, because the stomach is located away from the irradiated field (Adams et al.

1985 and Muraishi et al.1991) The advantages of the procedure include reducing systemic acidosis and urinary tract infection by acidic urine, and no mucus production. Furthermore, the submucosal tunnel technique for ureteral implantation can be easily applied to a wall of the gastric segment and the patient can void from the urethra. However, the operation requires significant surgical skill and is considerably hazardous, because the ischemic native bladder is usually buried in the frozen pelvis, caused by the previous operation and radiation therapy. The distal parts of the ureters are also embedded in fibrotic tissues and are sometimes not healthy. Thus, the indication for gastrocystoplasty is limited and other options may be required for complicated cases. Transverse colon pouch with a reconfigured colon segment for continent valve or ureteral reconstruction is a feasible alternative (Kato et al. 1999). This retrospective study of patients underwent transverse colon urinary diversion showed wide variety of indications. From the whole number of patients (43), 40 patients (93%) had malignant indications and 3 patients (7%) had benign indications. The malignant indications include Gynecologic malignancy in 22 patients (55%), including 20 patients with cancer cervix presented with vesico-vaginal fistula in 10 cases; postirradiation contracted bladder in 4 cases; recurrence with bladder infiltration in 2 cases, combined vesico-vaginal and recto-vaginal fistula in 2 cases, bilateral ureteral stricture in one case and associated bladder cancer in one case. One case of endometrial carcinoma presented with bladder infiltration and vesico-vaginal-intestinal fistula. One case of cancer of the vagina presented with recurrence and bladder infiltration after primary surgical management.

Malignant tumors of prostate in 10 patients (25%) including 8 patients with cancer of the prostate presented by urinary incontinence associated with post irradiation contracted bladder in 4 cases; recurrent bladder neck contraction associated with post irradiation contracted bladder in 3 cases and one case of recto-vesical fistula. Two patients of rhabdomyosarcoma of the prostate presented with postirradiation contracted bladder. Cancer of the rectum in 4 patients (10%) including 2 patients presented with recto-vesical fistula, one case presented with postirradiation contracted bladder and one case

presented with bladder infiltration. Sarcoma in pelvic bone in one patient (2.5%) presented with postirradiation contracted bladder and wound fistula. Benign indications were one case of hyper-reflexive bladder after polytrauma and two cases of neurogenic bladder dysfunction. The ideal urinary diversion should provide excellent continence, adequate capacity, and a low-pressure system and should result in minimal distortion of metabolism, anatomy and renal function. Further, it must have a low complication rate and be consistently technically feasible (Sullivan et al. 1998). Selection of an appropriate intestinal segment for bladder substitution is essential for success. Detubularized bowel segments provide greater capacity at lower pressure and require a shorter length of bowel than do intact segments (Bachor et al. 1993).

The transverse colon does not suffer the damaging effects of pelvic radiation, because of its high position in the abdomen. Moreover, it presents with an adequate blood supply for an appreciable extension, which allows ureterointestinal anastomosis using the antireflux technique (Beckley et al. 1982 and Schmidt et al 1985). In contrast, the ascending and descending colon, as well as the loops of the small intestine, used in the Indiana, Miami, Florida techniques and the Kock pouches are in the radiation field (Webster et al. 2003). The mechanism of continence in these techniques depends on the vitality and potential of cicatrization, which can be impaired by the effect of radiotherapy (Martinez et al. 2000). Consequently, it can result in the development of fistulas or ureteral stenosis and the loss of the intussusception due to partial or total necrosis of the valve (Gerharz et al. 2000).

The transverse colon made it possible to create a continent reservoir with a large capacity, low pressure, and high compliance (Bihle et al. 1991).

The ileal conduit has been the standard method of urinary diversion for many years, but alternative techniques were sought, once these high complication rates became apparent in previously irradiated patients. In 1969, Nelson reported the first results with the transverse colon conduit for irradiated patients (Nelson 1969). Long-term experience with the transverse colon

conduit from various groups has confirmed the excellent outcome and low complication rate associated with this technique. (Schmidt et al. 1985, Beckley et al. 1982 and Ravi et al. 1994). In 1989, Bihrlé *et al* introduced a continent transverse colon reservoir with an efferent segment constructed from a gastric tube. Recently, the results of a continent, nonrefluxing transverse colonic reservoir were presented. The investigators suggest that this technique is a safe and effective diversion and recommend it for patients treated by pelvic irradiation (Bihrlé et al. 1991).

There are several other potential advantages of TCC. The mobility and cephalad position of the transverse colon provide the ability to create a high ureterocolic or renal pelvis-to-colon anastomosis when insufficient ureteral length is present. In comparison to an ileal conduit, a TCC does not require a small bowel anastomosis with its potential for complications, especially in the presence of prior pelvic irradiation. Colonic stomas are associated with a decreased incidence of stomal complications compared to small intestinal stomas. Additionally, surgeons have greater latitude in determining stomal placement with the transverse colon compared to the ileum or sigmoid colon. The significant urinary electrolyte absorption is uncommon (Schmidt et al. 1976 and Mansson et al. 1987).

## 6.2. Complications

An early report on transverse colon conduits addressed postirradiation conduit construction in 22 adults. Eleven patients had a history of cervical cancer, and one had a history of endometrial cancer. Stents were not used, and no special antireflux anastomosis was created. Average follow-up was 18 months. Ureterocolic leakage or fistula occurred in two patients and ureterocolic stricture in a third patient. Hyperchloremic acidosis and stomal stenosis were not observed (Schmidt et al. 1976).

Schlesinger et al. reported on 59 patients with malignancies of the female reproductive tract undergoing colon conduit (50 patients) and ileal conduit (9 patients). Transverse colon and sigmoid colon segments were used equally in this report and results were similar. Ten serious complications related to the conduit occurred. Two patients had marked hydronephrosis, two developed fistulas, three needed revision, and one had a persistent anastomotic leak. The deaths of four patients, who died without evidence of



recurrent tumor were related to their conduit. Minor degrees of hydronephrosis were seen in one-third of the patients, and calcifications in the renal pelvis were noted in two patients (Schlesinger et al. 1979). Orr and colleagues examined conduit techniques in patients undergoing pelvic exenteration. The focus of the article was on the use of gastrointestinal staplers and ureteral stents, as well as on the section of bowel used. Of 119 patients, 16 patients had a transverse colon conduit, 97 had an ileal conduit, and 2 had a sigmoid colon conduit. In 8.7% urinary leak and fistula rate was observed. All of these leaks and fistulas occurred in patients with ileal conduits. Nephrectomy, stricture, and metabolic abnormality were infrequent (Partridge et al. 1982). The number of patients undergoing transverse colon conduit in this series is small, and detailed information in regard to length of the follow-up period is limited. Prior series present a nonrandomized comparison was made between stented versus nonstented ureters in gynecologic oncology patients undergoing transverse colon conduit. Intravenous pyelogram was performed at 6 months or sooner if a problem was suspected. Ureteral strictures occurred in 7 of 38 patients, 18%, of the nonstented group and 3 of 37, 8%, of the stented group. Leaks and fistulas occurred significantly more often in the nonstented group (3% vs 18%). Overall, the total complication rate was significantly higher in the nonstented group (Beddoe et al. 1987).

In our study transverse colon conduit in 20 patients was studied retrospectively with the mean period of follow-up of 52.2 months. In all cases direct anastomosis of the ureter to the conduit was done. None of the patients developed stricture or leak in the uretero-colonic anastomosis, one case developed mild unilateral hydronephrosis without need of intervention or deterioration of renal function in the follow-up period.

The Mainz III is a low-pressure, high-capacity, continent cutaneous urinary reservoir made exclusively of colon (40 cm of either ascending and transverse colon, or transverse and descending colon are used). Ileum is used for neither creating the pouch nor the efferent limb carrying the continent mechanism. The exclusive use of colon preserves the ileocaecal valve and the terminal ileum, and as a result, absorption of vitamin B12 by

the terminal ileum is not disturbed. In addition, there is no malabsorption of bile acids and/or fat, reducing the risk of stone (renal and gall) formation and steatorrhoea, respectively. Consequently, complications related to the malabsorption of liposoluble vitamins and calcium metabolism (Osteomalacia and osteoporosis) can be prevented (Benson and Olsson 2002).

The prevalence of vitamin B12 deficiency increases as people get older (Stabler et al. 1997); as documented by both low serum vitamin B12 levels and more recently by elevated levels of two vitamin B12-dependent metabolites, methylmalonic acid and total homocysteine, in the serum of older subjects (Savage et al. 1994). Some of these subjects have true pernicious anemia (1.9% of those aged  $\geq 65$  years), but most are thought to have malabsorption of protein bound vitamin B12. The natural history of protein-bound B12 malabsorption is unknown, especially because these individuals may absorb crystalline B12, which is found in small amounts in vitamin supplements and in food (Stabler et al. 1997). Vitamin B12 deficiency is defined as a serum B12 level of  $<190$  pg/ml (range 190-300). The prevalence of metabolically confirmed B12 deficiency was 14.5% in older outpatients in the early 1990s: Most clinically deficient patients have concentrations of methylmalonic acid of  $>500$  nmol/l (Behrend et al. 1995). Vitamin B12 deficiency may lead to severe hematological and neurological symptoms, which include megaloblastic anemia, peripheral neuropathy, optic atrophy, dementia and funicular myelitis (Spinal cord degeneration) (Lindgren et al. 1999). One of the remarkable changes with aging is the frequent development of atrophic gastritis and the inability to secrete gastric acid. This process was recently recognized to be caused by infection with *Helicobacter pylori* in most cases. The lack of gastric acid in atrophic gastritis may lead to small intestinal bacterial overgrowth and influence the absorption of vitamin B12 (Saltzman et al. 1998). Fujisawa et al. reported that 16.6% of patients with an ileocolic neobladder developed lower serum vitamin B12 levels after 5–6 years. The reported risk of vitamin B12 deficiency is 30% and 33% at 3 and 5 years in patients with an orthotopic Kock ileal neobladder (Fujisawa et al. 2000). Steiner et al. reported that 25% of patients with an ileocolic neobladder had low serum vitamin B12 levels and they recommended that

such patients must be identified and placed on lifelong parenteral vitamin B12 (Steiner et al. 2003). Terai et al. reported that the mean serum B12 level in patients with the Kock pouch (506 pg/ml) and the Indiana pouch (536 pg/ml) were lower than in patients with an ileal conduit (727 pg/ml). The mean serum B12 levels were not significantly different between patients with and without preoperative irradiation. A third of patients with Kock pouches and two-thirds with Indiana pouches were B12 malabsorbers, although no patients had megaloblastic anemia or neurological symptoms (Terai et al. 1997).

The previous studies about the transverse colon pouch by Leissner et al. 2000 and Stolzenburg et al. 2006 as well as our study, there was no cases of vitamin B12 deficiency in the follow-up period.

Resecting the ileocaecal valve leads to bacterial colonization of the small bowel, resulting in early deconjugation of the bile salts and disturbance of the enterohepatic circulation. In addition, the defecation frequency is 30% higher (diarrhoea) (Farnham and Cookson 2004).

In our study there was no cases of diversion related diarrhea or increase the defecation frequency. Various investigators report that all patients with catheterizable pouches are infected, yet most patients with chronic bacteriuria do not present with symptoms or complications (McDougal et al. 2002 and Elder et al. 1979). Several authors reported that, when kidneys were directly punctured to obtain urine cultures, there was no difference between refluxing and nonrefluxing systems in the incidence of bacteriuria (McDougal et al. 2002 and Gonzalez et al. 1987). Bacteriuria alone did not seem to present a danger for morbidity or a risk for a decrease in renal function except in patients with *Proteus* or *Pseudomonas* found in the urine cultures. It was concluded that only the latter patients should be treated (Wilson et al. 1994).

In our study of 43 patients only 3 cases (6.97%) of recurrent significant infection in the follow-up period were reported.

Incontinence is an important and debatable issue, with an incidence of 0.6–8% depending on the technique applied and the terminology of continence adopted (Farnham and Cookson 2004). The incidence of incontinence in CCD is difficult to evaluate due to lack of standard terminology and non-

validated questionnaires in retrospective series. In this study incontinence was strictly defined as any occurring leakage. There is no published consensus about the definition of incontinence. The Mainz pouch provides 'true continence', whereas continence of other pouches (i.e. Indiana) depends on catheterization at strict intervals to avoid urinary overflow and leakage. Continence of continent cutaneous urinary diversions is usually achieved with the aid of the Mitrofanoff principle, according to which the appendix or a tubularized bowel segment (Pseudoappendix) is embedded into the pouch wall (Between the mucosal and seromuscular layer), creating a flap valve mechanism. Incontinence is rare and can result from an inadequate length of the flap-valve mechanism or from continuously elevated reservoir pressure. Beside this flap-valve mechanism, ileocaecal valve plications, intussuscepted nipples, and/or hydraulic valves (i.e. Benckroun nipple) serve as continence mechanism in different types of urinary diversion (Natarajan et al. 200 and Benson et al. 1999).

The overall continence rates for most of these reservoirs are  $\approx 90\%$ , although 'continence' is not clearly defined. The continence rate of the Kock pouch was reported to be 77–89%, of the Florida pouch  $\approx 93\%$ , and of the Benckroun system  $\approx 93\%$ . Continence rates in larger series using the Mitrofanoff principle are 91–100% (Gerharz et al. 2001). Stein et al. reported on 300 patients who had a Mainz I continent urinary diversion with a follow up of  $> 5$  years (Mean 9.3, SD  $\pm 2.7$ ) (Stein et al. 2001). In our study of 23 patients with transverse colon pouch 19 patients (82.6%) were fully continent during follow up period and 4 patients (17.4%) required security pads. All patients used self catheterization with the frequency of catheterization 4-6 at day time and 1-3 at night. It was noticed that in the first few months postoperative the rate of catheterization is relative high, but it became better after that with improvement of pouch capacity. Of the 23 patients with transverse colon pouch included in this study, 14 patients (60.9%) had pouch capacity ranged from 300 to 400 ml; 6 Patients (26.1%) had pouch capacity less than 200 ml and 3 (13.4%) patients had pouch capacity more than 500 ml.

Most of the patients with small pouch capacity were in the 1<sup>st</sup> postoperative year. The mean pouch capacity was 297.4 ml.

Complications are related to the efferent limb and/or stomal stenosis, with rates of stenosis and difficulty in catheterization of 1.5–18% (Farnham et al. 2004). Stomal stenosis is the most common complication of an appendiceal efferent limb, occurring in 10–35% of patients (Harris et al. 2000). The main advantage of the Mainz III is the use of the large bowel to create the efferent limb; the latter has a wider lumen than the appendiceal segment, which often can only be catheterized by a small catheter (< 16 F). In these patients, regular flushing of the pouch to evacuate mucus can be difficult. Pouchoscopy is only possible using paediatric cystoscopes, reducing the facilities for manipulations, e.g. removal of pouch stones.

To avoid or minimize problems with pouch catheterization, the following are of paramount importance: proper fixation and stabilization of the efferent limb, creating a tension-free anastomosis and preventing angulation of the catheterizable channel.

In a previous study on the Mainz III, stomal stenosis appeared in six of 44 patients and was treated with endoscopic incision or Y-V plasty (Leissner et al. 2000). As an alternative, we prefer using buccal mucosa to correct stomal stenosis (Three of 12 patients with a Mainz I pouch). Leissner et al. reported an 86% continence rate after Mainz III pouch formation in irradiated patients; they created the efferent limb by leaving 5–6 cm of the oral or the aboral colonic end intact, and tapering it over an 18 F catheter (Leissner et al. 2000). Kato et al. reported using transverse colon for three patients after pelvic irradiation, and all were continent after surgery; they used a detubularized small colonic ring from the distal end of the segment to create the efferent limb (Kato et al. 2002). A similar technique was used by D'Ancona et al., 2005 in a previously irradiated female patient. Bochner et al. 2004 and Stein et al. 2005 created a flap-valve mechanism in ileocaecal pouches with the submucosal implantation of appendix in 27 and 14 patients, respectively, both studies reporting complete continence during the day and night.

Of our patients with transverse colon pouch, there were 3 cases (13.4%) of nipple insufficiency managed by nipple revision and two cases (8.7%) of outlet stenosis that required revision; correction of the efferent limb had to be combined with revision of the stoma, a second revision was needed in one case (4.35%) the urinary diversion was converted to a conduit. In regard to

patients with transverse colon conduit there was no stomal related complications. Pouch perforation is rare. None of these complications occurred in the present series.

The pouch stones occurred in only one case of transverse colon pouch (4.3%) the low rate of pouch stone could be related to the normal absorption in the terminal ileum and the unimpaired function of the ileocaecal valve.

Intestinal segments vary in terms of how they handle solutes. Length of bowel segment, surface area, duration of urinary exposure, solute concentration, pH, renal function, and urine osmolality all play a role. The reservoir surface is exceedingly difficult to estimate. No difference has been discerned between ileal and colonic mucosa with regard to sodium-absorbing capacity. However, in the colon, chloride absorption and bicarbonate excretion are more pronounced, and evidence increasingly suggests that inherent chloride absorption is maintained when in contact with urine (Kollias et al. 1984).

The effects of absorption of urine across the colon wall on renal function are minimized because of the mass contraction emptying of the segment and the resultant small residual volumes (Joseph et al. 1976).

In 1950, Ferris and Odel were the first to describe the unusual electrolyte pattern characterized by hypokalemia, hyperchloremic acidosis, and absorption of ammonia in patients with ureterosigmoid diversion (Ferris et al. 1991). The use of colon for urinary reservoirs may lead to serum hyperosmolality and subsequent decreased aldosterone release with increased antidiuretic hormone release. This metabolic disturbance results in highly concentrated urine from which the colonic mucosa will absorb more sodium and chloride. Classically, these patients become acidotic, and with close scrutiny, all have at least a mild degree of metabolic acidosis after continent diversion with colonic segments (Koch et al. 1991). The principal mechanism leading to the production of acidosis is thought to be ammonium reabsorption. Ammonia, ionized ammonium, and chloride are reabsorbed when ileum or colon is exposed to urine (Koch et al. 1991). The acid load comes mainly from the reabsorption of ammonium chloride. Quantitatively, hydrogen reabsorption is minimal and bicarbonate secretion is exceeded many times by ammonium reabsorption. Ammonia may diffuse freely across

the bowel mucosa, and, as urinary pH increases, absorption will increase. However, evidence suggests that reabsorption of ionized ammonium occurs; this can be seen at luminal pH 5 when ionized ammonia is present in only small amounts. Also, in brush border membrane studies, ammonium transport can be demonstrated against an ammonia concentration gradient (McDougal et al. 1995). If the sodium concentration in a urinary reservoir is increased, ammonium absorption is decreased. Recent evidence has suggested that ammonium absorption may occur through substitution for sodium in the sodium–hydrogen antiport, with the ammonium ion acting as a competitive inhibitor of sodium uptake (Stampfer et al. 1997). Evidence of ionized ammonium absorption through potassium channels has also been noted, although this is not thought to contribute significantly to acidosis (McDougal et al. 1995). Current treatment of hyperchloremic metabolic acidosis involves the use of alkalizing agents and/or blockers of chloride transport. Oral sodium bicarbonate is effective in restoring normal acid/base status, but intestinal gas formation can be a problem, and the dose is not easily predictable. Alternatively, sodium citrate may be given, but the taste is unpleasant. Sodium supplements may increase blood pressure or may cause fluid retention and pulmonary edema in patients at risk. If excessive sodium loads are undesirable, chlorpromazine or nicotinic acid may be used, although these are also not without significant adverse effects. They act through inhibition of cyclic adenosine monophosphate, thereby impeding chloride transport; when used alone, they will not correct acidosis but will alleviate the situation, allowing a reduced dose of alkalizing agents (McDougal et al. 1995). The key to successful management is proper diagnosis by exclusion of urinary infection and sepsis, as well as awareness of the salt-losing syndrome. Proper treatment includes catheter reinsertion to ensure good drainage and to minimize further chemical reabsorption, rehydration with intravenous normal saline, and correction of acidosis with sodium bicarbonate. In our study of all patients the significant metabolic acidosis which needed treatment occurred in 2.3%, but all other cases of metabolic acidosis was mild and required no treatment.

Hypokalemia and total body depletion of potassium may be seen with ileal and colonic urinary intestinal diversion, although more frequently with the



latter, as ileal segments absorb more potassium. In 1 study, patients with ureterocolonic diversion had a 30% decrease in total body potassium, and those with an ileal conduit had up to a 14% decrease (Williams et al. 1967). The potassium depletion is probably owing to renal potassium wasting as a consequence of renal damage, osmotic diuresis, and gut loss through intestinal secretion. The latter probably plays a relatively minor role quantitatively. It has been shown that ileal segments, when exposed to high concentrations of potassium in the urine, reabsorb some of the potassium, whereas colon is less likely to do so (Koch et al. 1990).

Therefore, treatment with potassium citrate is often most appropriate for patients with colonic reservoirs.

Bone demineralization is a worrisome potential long term effect of urinary intestinal diversion is bone demineralization, which has been most clearly demonstrated in children with rickets and adults with osteomalacia after ureterosigmoidostomy (Siklos et al. 1980). In these conditions, bone mineral lost is replaced by osteoid, resulting in decreased bone strength. The cause is complex, but long-term changes in acid– base balance are likely the major contributory factor. Chronic acidosis may affect the skeleton in 3 ways: (1) bone minerals, including calcium, carbonate, and sodium, act as buffers in exchange for hydrogen ions, thus decreasing skeletal calcium content (McDougal et al. 1988). (2) Acidosis impairs hydroxylation of 25-hydroxycholecalciferol in the kidney, and activated vitamin D deficiency results in bone mineralization defects (Lee et al. 1977) and (3) acidosis activates osteoclasts, resulting in bone resorption (Arnett et al. 1986). In addition, poor intestinal absorption of calcium and vitamin D may occur after ileal resection. Patients with preexisting renal disease are prone to acidosis and may have impaired activated vitamin D production related to tubular cell damage, and so they are at particular risk. Changes in acid– base balance may be subtle, and, as experiments in animals with urinary diversion have demonstrated, oral supplementation with bicarbonate can prevent demineralization in the absence of significant systemic acidosis (McDougal et al. 1988). Some institutions now recommend oral sodium bicarbonate when base deficit is 2.5 mmol/l (Stein et al. 1997). Patients may be asymptomatic, may report pain in weight-bearing joints, or may present with fractures. Long-

term follow-up of patients with myelomeningocele with intestine in the urinary tract has revealed an increased number of fractures and an enhanced intervention rate for spinal curvature with increased incidences of nonunion and delayed healing compared with controls treated with intermittent catheterization (Koch et al. 1992). This finding suggests that, although severe defects in bone demineralization are not often seen, it is likely that many patients have subtle alterations in bone mineral density (BMD) with prolonged follow-up after urinary intestinal diversion. Women, who are susceptible to postmenopausal osteoporosis, and young patients, who are growing and may live with urinary diversion for many years, seem to be at greatest risk. Laboratory tests may be normal despite symptoms, although in general, serum calcium and phosphate are reduced, and alkaline phosphatase is elevated (Mundy et al. 1992). Parathormone levels usually are not elevated, and serum levels of activated vitamin D may be normal. Radiologic appearances are usually also normal. Bone densitometry is useful but may not detect subtle changes without repeat testing. Bone biopsy may be the only way to confirm diagnosis. Therefore, follow-up is difficult, especially because the process takes many years. With normal renal function, severe bone defects are not common after continent diversion with ileal or colonic reservoirs. The risk may be slightly higher with colonic reservoirs in that calcium reuptake is less efficient from colonic than from ileal segments (Mundy et al. 1992). Follow-up studies have revealed contrasting findings. Normal BMD has been reported in patients with orthotopic ileal reservoirs up to 17 years after urinary diversion (Tschopp et al. 1996). Also, bone mineralization was not affected in patients with continent cecal reservoirs followed for 5 years (Davidsson et al. 1995). A recent study demonstrated significantly decreased BMD and increased urinary pyridinium cross-links associated with metabolic acidosis after Indiana and Kock pouch formation (Kawakita et al. 1996). Also, urinary diversion with the ileal Kock reservoir reduced BMD of the spine and total skeleton compared with normal, age-matched controls (Poulsen et al. 1997). Additional prospective studies with longer follow-up are required before the risks of bone demineralization and subsequent fracture rates associated with continent diversion are known.

In our study there was no incidence of bone symptoms or pathologic fracture during the period of follow up.

Bowel mucosa secretes mucus made up of a glycoprotein core of long-sequence amino acids with a molecular weight of 2 to 20 million Dalton and side chains of monosaccharides wrapped around the protein core (George et al. 1992). The glycoprotein core is formed by the rough endoplasmic reticulum of goblet cells. In solution, the glycoprotein becomes hydrated and viscous. Continent urinary diversions produce around 35 g/day of mucus (Bushman et al. 1994). In the early postoperative period, indwelling catheters must be carefully irrigated to prevent initial mucous buildup within the diversion (Varol et al. 2004). Some investigators report that an increase in mucous production may be an early sign of urinary infection and irritation in the diversion (Leibovitch et al. 1991). Early or late mucous retention has been reported in 0.58% to 2% and in 3% of patients, respectively (Abol-Enein and Ghoneim 2001). N-acetylcysteine and urea are effective mucolytic agents (Marriott et al. 1983). N-acetylcysteine is a water-soluble thiol that reduces the disulfide bonds in the mucus. In contrast, carbocysteine causes mucous precipitation rather than dissolution. Successful dissolution of a mucous plug in an ileal ureter has been reported after initial instillation of 300 ml of 1% N-acetylcysteine through a nephrostomy tube, followed by oral N-acetylcysteine 700 mg 4 times daily (Benderev et al. 1988). Irrigation of urinary diversions with N-acetylcysteine at smaller volumes and higher concentrations (30 ml; 20%) also has been found to be effective. Urea appears to break the hydrogen bonds within mucus and is faster and more potent than N-acetylcysteine (Bushman et al. 1994). In vitro, 12 g urea per 100 g mucus produced 90% and 100% dissolution of mucus within 5 minutes and 30 minutes, respectively. Once a large mucous plug is formed, no drug treatment may be effective, and manual evacuation through a large resectoscope sheath is most beneficial (Haupt et al. 1990). Oral therapy with ranitidine has been reported to decrease mucous production in patients with urinary diversion. However, in another prospective, randomized study of patients with urinary diversion, intake of ranitidine or aspirin produced no change in mucous production (O'Dow et al. 2001). Whether long-term adaptation of bowel mucosa incorporated into urinary diversion leads to

decreased mucous production is controversial. Some investigators report decreased mucus over time (Hendren et al. 1990), but others do not (level 3) (Murray et al. 1987). Ileal mucosa appears to atrophy over time when exposed to urine (Gatti et al. 1999); however, colonic mucosa is preserved and retains its mucus and immunoglobulin secretory capacities (Mansson et al. 1985). A minority of patients with recurrent mucus retention must be made aware of the importance of this problem, should be instructed in periodic catheter irrigation and mucous evacuation, and should be offered a trial of medical therapy with N-acetylcysteine or Urea.

### **6.3. Uretero-intestinal anastomosis**

Uretero-intestinal anastomosis is considered one of the most critical operative steps during construction of continent reservoirs. Protection of the upper urinary tracts is one of the ultimate goals of successful continent urinary diversion. Except in ureterosigmoidostomies, considerable controversy exists regarding whether to do direct ureterointestinal anastomosis or to perform antirefluxing ureteral implantation. It has been known that an important number of patients may die during the follow up period only due to deterioration of the upper urinary tract (Mesrobian et al. 1988). Some authors maintain that an antireflux mechanism is important in chronically infected continent cutaneous reservoirs (Volkmer et al. 2006). Others found that direct anastomosis was associated with lower incidence of uretero-intestinal strictures which can be more harmful than reflux. Various techniques of nonrefluxing and refluxing ureteric implantation have been developed with the aim of reducing the theoretical risk of pyelonephritis and renal deterioration. However, the search for the 'ideal' anastomosis technique continues (Hohenfellner et al. 2002). Nonrefluxing uretero-intestinal implantation results in stricture rates of 2.2–3.8%, by contrast, Hohenfellner et al. reported an obstruction rate of up to 30% after antirefluxive implantation; they concluded that a direct refluxing ureteric implantation in low-pressure, high capacity reservoirs is superior, as it has a minimal risk of anastomotic obstruction and subsequent deterioration of kidney function; other groups agree with this (Hela et al. 1993 and Echtle et al. 2000). The ideal uretero-intestinal anastomosis technique should include the technical simplicity and the surgical versatility i.e. suitable for all types of the ureters including normal dilated,

short and irradiated ureters. Ideally it also allows a non obstructed unidirectional flow of urine with minimal rate of stenosis and/or need for surgical revision. In addition the use of foreign material like staples or meshes should be avoided and the anti-reflux system should be constructed with minimal use of additional length of bowel segment. Furthermore it is preferable if retrograde endoscopic manipulation is feasible (Mesrobian et al. 1988).

Although reflux disappears or is significantly decreased in grade if the capacity of a urinary reservoir is increased making reflux nephropathy unlikely, the principle of protecting the upper tract by anti-refluxing implantation persists. Anti-refluxing ureterointestinal anastomosis has been performed from the beginning of continent urinary diversion regardless of the type of bowel segment used to create a low, high capacity reservoir (Lopez Pereira et al. 2001). However, the techniques described by Le Duc and Kock et al. caused ureteral obstruction in up to 30% of cases (Le Duc et al. 1987) and were later replaced by Studer implantation or by more sophisticated and less popular techniques used at only a few centers (Abol-Enein et al. 1995). The obstruction rate of the submucosal tunnel in the ileocecal Mainz pouch I depends significantly on the grade of ureteral dilatation. The same incidence was noted by Kohul et al. with a 6.2% and 15.8% ureteral obstruction rate in nondilated and dilated systems, respectively (Kouhl et al. 1996). Briefly, the drawback of antirefluxing implantations is the high rate of ureterointestinal obstruction. Only a few groups have reported their experience with refluxing ureteral implantation. In 1993 Helal et al. reported a decreased incidence of obstruction from 13.3% to 4.9% when normal ureters were implanted directly mucosa-to-mucosa into a Florida pouch (Helal et al. 1993). Reflux was documented in 7% of directly implanted renal units postoperatively. A similar incidence of 13% “nonrefluxing obstructions” observed by Pantuck et al. was also decreased to 1.7% by direct implantation (Pantuck et al. 2000). In a recently described modification of the ileal S pouch ureteroileal stenosis using a direct implantation technique was noted in 1 of 52 patients (2%) (Constantinides et al. 2001). Reflux was evident in 5 of 88 implanted ureters, which is only marginally higher than the 2% to 3.3% in patients with an anti-refluxing ureteral anastomosis. Ehtle et al. reported no reflux in 381 ureters

implanted by the same buttonhole technique as described for orthotopic ileal bladder substitution (Echtle et al. 2000). The incidence of obstruction was 3%. Animal experiments with long-term follow up of continent cutaneous urinary diversion are not available but there are data available on refluxing and anti-refluxing ureteral implantation performed in dogs with ileal bladder augmentation. In these studies damage to the upper urinary tract, as measured by the glomerular filtration rate, was the same after direct and anti-refluxing ureteral implantation (Kristjansson et al. 1996). When considering these results together, refluxing ureteral implantation seems to be possible regardless of the type of bowel segment used for urinary diversion and without the risk of consecutive loss of renal function. The literature offers some possible explanations for this phenomenon. An aspect is the relative pressure between the pouch and ureter. No one has measured the pressure in the ureter before its entrance into the pouch but it is known from animal studies that pressure in the ureter during contraction is higher than pressure in the pouch. The course of the ureter after a pouch is constructed must also be considered. Almost every ureterointestinal anastomosis has some kind of hypomochlion, which is caused by smooth kinking of the ureter during its course through the pouch wall. The combination of the pressure relationship between the pouch and ureter and some type of artificial ureteral obstruction may explain the fact that reflux seldom develops even after refluxing ureteral implantation in low pressure, high capacity reservoirs (Lennon et al. 1991). Radiation is responsible for damage to the intestinal and ureteric blood supply; the subsequent ischaemia results in a greater incidence of leakage or stenosis at the site of ureterointestinal anastomosis, malfunction of the stoma, fistulae, infection and/or dehiscence. It is well established that the use of irradiated bowel for urinary diversion has a high postoperative complication rate of 28– 90% (Bochner et al. 2005).

Wammack et al. 2002 reported a four-fold and Wilson et al. 1994 a five-fold increase in complication rates in irradiated patients. Recently, Wilkin et al. reported that their radiotherapy group had an 83% complication rate, vs 57% in the nonirradiated group, and that secondary surgical interventions were required more often in irradiated patients. Uretero-enteric complications present a significant proportion of pouch-related complications after pelvic

radiation, of 22–37% (Wilkin et al. 2002). Nonirradiated large bowel segments, ascending or descending, alone or together with transverse colon, have been used for urinary diversion. As the Mainz III reservoir is in the upper abdomen, ureters can be cut at a very high level (out of the irradiation field) ensuring an excellent capillary blood supply and reducing the risk of complications at the implantation site. This was confirmed by Leissner et al., who reported a low complication rate with the Mainz III in irradiated patients (Leissner et al. 2000). Reports on previously irradiated patients showed better results for the colon pouch and the flap valve as a continence mechanism than other techniques using irradiated bowel (Karsenty et al. 2005). Stein et al. and Bochner et al. recommend the caecum for creating the pouch, while the terminal ileum substituted the distal part of the ureter (uretero-ileal anastomosis), the ileocaecal valve serving as the antireflux mechanism (Bochner et al. 2005). Reservoir-related complications include pouch stones and urinary leakage, each with an incidence of  $\approx 10\%$  (Farnham and Cookson 2004). In our group of patients direct ureterointestinal anastomosis without antireflux implantation is used in all cases of transverse colon conduit also in all cases of transverse colon pouch, there were 5 cases (21.7 % of cases of transverse colon pouch) of reflux with no consequences, despite using a refluxing implantation technique, and there was one case (2.32% of all cases) of stenosis of the implanted ureters. Even at long-term follow up no deterioration in kidney function was observed and there was no recurrent obstruction. Although routine scintigraphy was not performed, normal serum creatinine, absent kidney dilatation and stable renal parenchymal thickness on sonography are important and certain signs of stable kidney function. Although follow-up in some of patients is still short, we emphasize the observation that no obstruction developed in 42 (97.7%) of 43 cases included in our study and 18 of 20 preoperatively dilated renal units returned to normal within 3 months postoperatively. Therefore, we believe that anti-refluxing ureterointestinal anastomosis in low pressure, high capacity reservoirs is unnecessary. The hypothesis of anti-refluxing implantation was adopted from older forms of urinary diversion and its necessity in more recent diversion techniques has never been demonstrated.



In our series of refluxing implantation there was no loss of kidney function and the rate of obstruction was decreased to 2.3%.

#### **6.4. Quality of life**

Quality of life (QOL) has been an issue in medical research for more than 20 years and many authorities now regard it as a key measurement in clinical trials. However, many issues in QOL after urinary diversion remain controversial (Gerharz et al. 2005).

WHO concept of health and quality of life is defined as “an individual’s perception of their position in life in the context of the culture and value system in which they live and in relation to their goals, expectations, standards and concerns” (Bowling 1997). It is a broad ranging concept affected in a complex way by the person’s physical health, psychological state, and level of independence, social relationships and their relationship to other features of their environment. More recent proposals focus on outcome models that should be empirically testable and clinically relevant (Koller and Lorenz 2002).

Aaronson defined quality of life as “a multi-dimensional construct composed minimally of functional status, disease related and treatment related symptoms, psychological functioning and social functioning.” However it is doubtful whether the introduction of health related quality of life has enhanced the ability to determine what to include and what to leave out since it is unlikely that one could divide quality of life into its health and nonhealth related components (Aronson 1988). When assessed in patients quality of life is not related to health but rather it is related to disease and in particular to a specific disease (Bowling 1997). The critical model of disease is defined by a combination of the biological model of disease and the psychosocial model in which the patient suffers and seeks help from the doctor. This viewpoint is different from the having fun stereotype of good quality of life (Lorenz 1999). A possible danger of ignoring that QOL have little to do with health status is that patients with physical limitations due to diseases or to old-fashioned surgical procedures are labeled as having lower QOL than patients with a modern type of reconstruction or some average or normal individual. Such reasoning could lead to serious ethical consequences in the perception of



disabled individuals. It has even been suggested that measuring QOL is counterproductive and would be better replaced by a more easily understood assessment of common factors in perceived health status (Smith et al. 1999).

Nevertheless it is important to study health related aspects of malignant disorders and their different treatments but we should be more careful with how to use the term quality of life.

There are variety of measuring modalities including open/structured/face-to-face interview, telephone interview, self-report and the multitude of generic and disease specific questionnaires available (Cookson et al. 2003 and Clark et al. 1985).

It is important to understand that each of these instruments measures different aspects of patient experience. Some instruments such as the RAND 36-Item, Short Form (SF-36) and Quality-of-Life Questionnaire (QLQ)-C30 combine various components that are thought to be associated with quality of life; physical limitations, mental distress, social interaction, symptoms and so on. A problem is that each of these components may be valued differently by different people. Thus physical activity may be more important than social interaction for some individuals and vice versa for others. Moreover where there are subscales, the outcome on one e.g pain may be negative while the outcome on another e.g social relationship may be high. In the absence of a model that explains how each of these aspects contributes to quality of life it is impossible to draw firm conclusions. In addition some measures are based on actual patient comments and reflect their viewpoints for example the Nottingham Health Profile, while others are based on professional opinion such as the Functional Assessment of Cancer Therapy (FACT)-General (G). Since it is known that patients and physicians do not always agree on which matters are of primary concern, this becomes a serious consideration. These observations make it imperative that potential researchers should examine the items prior to choosing a measure particularly in the light of what is feasible for the treatment to achieve (Pazooki et al. 2005). A short form questionnaire was done for patients who underwent transverse colon diversion. It showed good acceptance by patients and families. Although a

more detailed questionnaire is needed to evaluate all aspects of quality of life. The relatively small number of patients and the retrospective nature of the study in addition to the lack of prospective matching of co-morbidities weaken the study to some extent. Comparison of this issue among different forms of urinary diversion with the available data is difficult if not impossible.

## **7. Conclusion and recommendations**

- I. The results of high urinary diversion using transverse colon in patients with previous history of irradiation are excellent.
- II. This retrospective study showed that the indications of transverse colon diversion was not limited to patients with history of irradiation as 21.7% of patients included in this study had no history of irradiation.
- III. Transverse colon is bowel segment of choice for urinary diversion in previously irradiated patients to avoid the complications of using irradiated bowel.
- IV. Nonrefluxing uretero-intestinal implantation techniques are not needed in low pressure urinary reservoirs.
- V. The results of transverse colon pouch were very encouraging, with excellent continence rates. We suggest that this technique of continent urinary diversion should be considered as a suitable alternative to other methods.
- VI. Although most of patients included in this study have history of irradiation and previous operation the results was excellent, so it expected that the results will be better if the indications of this technique are generalized to all patients in need of urinary diversion.
- VII. We recommend prospective study in larger number of patients comparing the outcome of transverse colon diversion in patients with history of irradiation, with the outcome in patients in need of urinary diversion without history of irradiation, with consideration and more detailed evaluation of quality of life in both groups.

## 8. References

- Abol-Enein H, Ghoneim M A (1994) Novel uretero-ileal re-implantation technique: the serous-lined extramural tunnel. A preliminary report. J Urol 151: 1193–1198
- Abol-Enein H, Ghoneim M A (1995) Further clinical experience with the ileal W neo-bladder and a serous-lined extramural tunnel for orthotopic substitution. Br J Urol 76: 558
- Abol-Enein H, Ghoneim M A (1999) Serous lined extramural ileal valve: a new continent urinary outlet. J Urol 161: 786
- Abol-Enein H, Ghoneim M A (2001) Functional results of orthotopic ileal neobladder with serous-lined extramural ureteral reimplantation: experience with 450 patients. J Urol 165: 1427–1432
- Adams MC, Mitchell ME, Rink RC (1985) Gastrocystoplasty: An alternative solution to the problem of urological reconstruction in the severely compromised patients. J Urol 140: 1152–6
- Akerlund S, Forssell-Aronsson E, Jonsson O, et al. (1991) Decreased absorption of  $^{22}\text{Na}$  and  $^{36}\text{Cl}$  in ileal reservoirs after exposure to urine: an experimental study in patients with continent ileal reservoirs for urinary or fecal diversion. Urol Res 19: 249–252
- Alcini E, D'Addessi A, Racioppi M, et al. (1993) Results of 4 years of experience with bladder replacement using an ileocecal segment with multiple transverse teniomyotomies. J Urol: 149:735– 738
- Altwein J E, and Hohenfellner R (1975) Use of the colon as a conduit for diversion. Surg. Gynecol. Obstet 140: 33–38
- Arnett TR, Dempster DW (1986) Effect of pH on bone resorption by rat osteoclasts in vitro. Endocrinology 119:119 –124
- Aronson N K (1988) Quality of life: what is it? How should it be measured? Oncology (Williston Park) 2: 69-78
- Bachor R, Hautman R (1993) Options in urinary diversion: a review and critical assessment. Semin Urol 11:235–50
- Beckley S, Wajsman Z, Pontes J, Murphy G (1982) Transverse colon conduit: A method of urinary diversion after pelvic irradiation. J Urol 128: 464–468

- Beddoe A M, Boyce J G, Remy J C, Fruchter R G, and Nelson J R (1987) Stented versus nonstented transverse colon conduits: A comparative report. *Gynecol. Oncol.* 27: 305–313
- Behrend C, Jeppesen P B, Mortensen P B (1995) Vitamin B12 absorption after ileorectal anastomosis for Crohn's disease: effect of ileal resection and time span after surgery. *Eur J Gastroenterol Hepatol* 7: 397
- Bejany DE, Politano VA (1988) Stapled and nonstapled tapered distal ileum for construction of a continent colonic urinary reservoir. *J Urol* 140: 491–4
- Benderev TV (1988) Acetylcysteine for urinary tract mucolysis. *J Urol* 139:353–354
- Benson MC, Olsson CA (1999) Continent urinary diversion. *Urol Clin North Am* 26: 125–45
- Benson MC, Olsson CA (2002) Cutaneous continent urinary diversion. In Walsh PC, Retik AB, Vaughan ED Jr, Wein AJ eds, *Campbell's Urology*, 8th ed, Vol. 4, Chapt. 107. Philadelphia: W.B. Saunders: 3789–3831
- Berthrong M (1986) Pathologic changes secondary to radiation. *World J Surg* 10:155–70
- Bihrlé R, Foster RS, Stiede CP (1989) Creation of colon-gastric composite reservoir: a new technique. *J Urol* 141: 1217-1220
- Bihrlé R, Klee L W and M C Adams et al. (1991) Transverse colon-gastric tube composite reservoir. *Urology* 37: 36–40
- Bihrlé R, Klee L W Adams et al. (1991) Early clinical experience with the transverse colon-gastric tube continent urinary reservoir. *J Urol* 146: 751–753
- Bissada N K (1995) Management of radiation-induced vesicovaginal fistulae. In: M A S Jewett, Editor, *Urological Complications of Pelvic Surgery and Radiotherapy*, Isis Medical Media, Oxford: 68–73
- Bochner BH, McCreath WA, Aubey JJ et al. (2005) Use of an ureteroileocecal appendicostomy urinary reservoir in patients with recurrent pelvic malignancies treated with radiation. *Gynecol Oncol*; 94: 140–6
- Boronow RC (1986) Repair of the radiation-induced vaginal fistula utilizing the Martius technique. *World J Surg* 10: 237–48
- Bowling A (1997) *Measuring Health: A Review of Quality of Life Measurement Scales* 1997

- Bowyer G W, Davies T W (1987) Methotrexate toxicity associated with an ileal conduit. *Br J Urol* 60: 592–593
- Bricker EM (1950) Bladder substitution after pelvic evisceration. *Surg Clin N Amer* 30:1511-1520
- Bricker E M, Eisman B (1950) Bladder reconstruction from cecum and ascending colon following resection of pelvic viscera. *Ann Sur* 132: 77-84
- Bricker E M (1950) Bladder substitution after pelvic evisceration. *Surg Clin N Am* 30: 1511
- Bushman W, Howards SS (1994) The use of urea for dissolution of urinary mucus in urinary tract reconstruction. *J Urol*: 151:1036 –1037
- Carmel, R (1996) Prevalence of undiagnosed pernicious anemia in the elderly. *Arch Intern Med* 156: 1097
- Carmel, R (1997) Cobalamin, the stomach and aging. *Am J Clin Nutr* 66: 750
- Chapple C, Turner Warwick R (2005) Vesicovaginal fistula. *Br J Urol* 95: 193–214
- Clark T, Wells N, Chang S, Dutta S, Smith J r, Cookson M (1985) Prospective assessment of health related quality of life (HRQOL) urinary diversion following radical cystectomy and urinary diversion: comparison of orthotopic neobladder versus ileal conduit patients. *J Urol suppl* 171: 79,185
- Constantinides C, Manousakas T, Chrisofos M, Giannopoulos A (2001) Orthotopic bladder substitution after radical cystectomy: 5 years of experience with a novel personal modification of the ileal S pouch. *J Urol* 166: 532
- Cookson M S, Dutta S C, Chang S S, Clark T, Smith, J A, Wells N (2003) Health related quality of life in patients treated with radical cystectomy and urinary diversion for urothelial carcinoma of the bladder: development and validation of a new disease specific questionnaire. *J Urol* 170-1926
- Codonnier JJ (1962) Uretero-ileocystoplasty: a review of late results in four cases. *Br J Urol. Jun* 34:200-206
- D’Ancona CA, Cavaller AR, Ferreira U et al. (2005) Continent urinary diversion in patients with pelvic irradiation: an alternative utilizing transverse colon reservoir. *Int Urol Nephrol* 37: 499– 500

- 
- Davidsson T, Akerlund S, White T (1996) mucosal permeability of ileal and colonic reservoirs for urine. *Br J Urol* 78: 64–68
  - Davidsson T, Lindergard B, and Obrant K. (1995) Long-term metabolic effects of urinary diversion on skeletal bone: histomorphometric and mineralogic analysis. *Urology* 46: 328 –333
  - Douglasn, Dahl W, Scott Mc, Dougal, Campbell-Walsh *Urology*, 9th ed. (2007) Saunders, an Imprint of Elsevier Chapter 80 – Use of Intestinal Segments in Urinary Diversion. 1234-1242
  - Ehtle D, Müller E, Kontaxis D, Wöhr M, Frohneberg D. (2000) Why it really works so well: Neue Ureteimplantatiuon bei Ersatzblasen. *Aktuelle Urol* 31 : 263–268
  - Ehtle D, Muller E, Kontaxis D, Wöhr M, Frohneberg D (2000) Why it really works so well. *Akt Urol* 31: 261
  - Edsmyr R, Moberger G, Wadstrom L (1971) Carcinoma of the bladder: cystectomy after supervoltage therapy. *Scand J Urol Nephrol* 5: 215
  - Edwards R H (1984) Hyperammonemic encephalopathy related t ureterosigmoidostomy. *Arch Neurol* 41:1211–1212
  - Eifel PJ, Levenback C, Wharton JT, Oswald MJ (1995) Time course and incidence of late complications in patients treated with radiation therapy for FIGO stage IB carcinoma of the uterine cervix. *Int J Radiat Oncol Biol Phys* 32:1289–300
  - Eifer K, Kavalier E, Rodriguez L, RosenblumN, Raz S. Tenyear (2003) Experience with transvaginal vesicovaginal fistula repair using tissue interposition. *J Urol* 169:1033–1036
  - Elder DD, Moisey CU, Rees RW. (1979) A longterm follow up of the colonic conduit operation in children. *Br J Urol* 51: 462–465
  - Farnham S B, Cookson M S (2004) Surgical complications of urinary diversion. *World J Urol* 22 : 157–167
  - Ferreira U, Netto NR, D'Ancona CAL, Esteves SC (1990) Derivacão urinaria apoas radioterapia no carcinoma urotelial da bexiga. *J Bras Urol* 16: 247
  - Ferreira U, Rodrigues Netto Jr and R. Lucena (2000) The transverse colonic reservoir: The Unicamp technique. *BJU Int* 85: 486–489
-

- Ferris D O, Odel H M (1950) Electrolyte pattern of the blood after bilateral ureterosigmoidostomy. JAMA:142: 634–640
- Fisch M, Riedmiller H, Hohenfellner R (1991) Pyelotransverse pyelocolostomy; An alternative method for high urinary diversion in patients with extended bilateral ureter damage. Eur Urol 19: 142-149
- Fisch M, Wammack R, Hohenfellner R (1996) Kolon-transversum-ascendens / descendens Pouch. Akt Urol 27: I-VIII
- Fossa S D, Heilo A, and Bormer O. (1990) Unexpectedly high serum methotrexate levels in cystectomized bladder cancer patients with an ileal conduit treated with intermediate doses of the drug. J Urol 143: 498 –501
- Fujisawa M, Nakamura I, Yamanaka N, et al. (2000) Changes in calcium metabolism and bone demineralization after orthotopic intestinal neobladder creation 163: 1108-1111
- Fujisawa M, Gotoh A, Nakamura I, Hara I S, Okada H, Yamanaka N et al. (2000) Long-term assessment of serum vitamin B(12) concentrations in patients with various types of orthotopic intestinal neobladder. Urology 56: 236
- Gallo AG (1946). A Proposito de operacion de Triana: Nueva tecnica de exclusion de la vejiga. Bol Trab Acad Argentina Cirujanos 30: 604-610
- Gatti R, Ferretti S, Bucci G et al. (1999) Histological adaptation of orthotopic ileal neobladder mucosa: 4-year follow-up of 30 patients. Eur Urol 36: 588 – 594
- Gerharz EU, Kohl k, Weingartner et al. (1997) Complications related to different continence mechanisms in ileocecal reservoirs. J Urol 158: 1709– 1713
- Gerharz EW (2001) Auf der Suche nach dem heiligen gral': das efferente segment in der kontinenten kutanen harnableitung. Aktuelle Urol 32: 291– 301
- Gerharz E W, Mansson A, Hunt S, Skinner E C, Mansson W (2005) Quality of life after cystectomy and urinary diversion: An evidence based analysis. J Urol 174: 1729
- Gilchrist R K, Merricks J W, Hamlin M H, Rieger IT (1950) Construction of substitute bladder and urethra. Surg Gynecol Obstet 90:752



- Goldstein MJ, Melamed MR, Grabstald H et al. (1967) Progressive villous atrophy of the ileum used as a urinary conduit. *Gastroenterology* 52: 859–864
- Goligher JC (1969) Surgical anatomy of the colon, rectum and anal canal. In: Turell R (ed). *Diseases of the Colon and Anorectum* (2nd ed). Philadelphia: WB Saunders
- Gonzalez R, Reinberg Y (1987) Localization of bacteriuria in patients with enterocystoplasty and nonrefluxing conduits. *J Urol* 138: 1104–5
- Goodwin W E, Harris A P, Kaufman J J, Beal J M (1953) Open transcolonic ureterointestinal anastomosis; a new approach. *Surg Gynecol Obstet* 97: 295
- Gros DA, Dodson JL, and Lopatin UA. (2000) Decreased linear growth associated with intestinal bladder augmentation in children with bladder exstrophy. *J Urol* 164: 917–920
- Haie-Meder C, A. Kramar, P, Lambin et al. (1994) Analysis of complications in a prospective randomized trial comparing two brachytherapy low dose rates in cervical carcinoma. *Int J Radiat Oncol Biol Phys* 29: 953–960
- Hancock KC, Copeland L J, Gershenson et al. (1986) Urinary conduits in gynecologic oncology. *Obstet Gynecol* 67: 680–684
- Harris CF, Cooper CS, Hutchenson JC, Snyder HM (2000) 3rd. Appendicovesicostomy: the Mitrofanoff procedure. 15-year perspective. *J Urol* 163: 1922–1926
- Haupt G, Pannek J, Knopf HJ, et al (1990). Rupture of ileal neobladder due to urethral obstruction by mucous plug. *J Urol* 144: 740–741
- Hautmann, R E, Schumacher M, Gschwend J E, Studer U E, Volkmer BG (2006) Long-term results of standard procedures in urology: The ileal neobladder. *World J Urol* 122: 124–129
- Helal M, Pow-Sang J, Sanford E, Figueroa E, Lockhart J (1993) Direct (nontunneled) ureterocolonic reimplantation in association with continent reservoirs. *J Urol* 150: 835–7
- Hendren WH, Hendren RB (1990) Bladder augmentation: experience with 129 children and young adults. *J Urol* 144: 445–453
- Hinman F, Weyrauch H M (1989): A critical study of different principles of surgery: cervical carcinoma. *J Urol* 141:1347–1349

- 
- Höckel M (1999) Pelvic recurrences of cervical cancer. *J Pelvic Surg* **5**: 255–266
  - Hohenfellner R, Black P, Leissner J, Allhoff EP (2002) Refluxing ureterointestinal anastomosis for continent cutaneous urinary diversion. *J Urol* **168**: 1013–7
  - Hossain M. (1970) The osteomalacia syndrome after colocystoplasty: a cure with sodium bicarbonate alone. *Br J Urol* **42**:243–245
  - John E, Skandalakis, Gene L, Colborn, Thomas A. Weidman, Roger S. Foster Jr, Andrew N, Kingsnorth, Lee J, Skandalakis, Panajiotis N, Skandalakis, Petros S, Mirilas (2004) *Skandalakis' Surgical Anatomy* edition 3, Chapter 18 large intestine and anorectum
  - Jordan G, Schellhammer PF (1987) Complications after pelvic irradiation of urologic and gynecologic malignancy. *AUA Update Series VI*: 2–7
  - Joseph D, Schmidt, M D, Herbert J, Buchbaum M D, Eliasc, Jacobo M D (1976) Transverse colon conduit for supravescical urinary diversion. *Urology* vol 3:123–30
  - Karsenty G, Moutardier V, Lelong B (2005) et al. Long-term follow-up of continent urinary diversion after pelvic exenteration for gynecologic malignancies *97*: 524–8
  - Kato H, Igawa Y, Komiyama I, Nishizawa O (2002) Continent urinary reservoir formation with transverse colon for patients with pelvic irradiation. *Int J Urol* **9**: 200–3
  - Kato H, Igawa Y, Nishizawa O (1999) Transverse colon pouch with total replacement of the ureter by reconfigured colon segment. *J Urol* **161**: 1902–1903
  - Kawakita M, Arai Y, Shigeno C (1996) Bone demineralization following urinary intestinal diversion assessed by urinary pyridinium cross-links and dual energy x-ray absorptiometry. *J Urol* **156**: 355–359
  - Koch MO, McDougal WS (1988) Bone demineralization following ureteroileal anastomosis; an experimental study in rats. *J urol* **140**: 856–859
  - Koch MO, and McDougal WS (1985) The pathophysiology of hyperchloremic metabolic acidosis after urinary diversion through intestinal segments. *Surgery* **98**: 561–570
-

- Koch MO, Gurevitch E, Hill DE, et al. (1990) Urinary solute transport by intestinal segments: a comparative study of ileum and colon in rats. *J Urol* 143:1275–1279
- Koch MO, McDougal WS, Hall MC (1992) Long-term metabolic effects of urinary diversion: a comparison of myelomeningocele patients managed by clean intermittent catheterization and urinary diversion. *J Urol* 147: 1343–1347
- Koch MO, McDougal WS, Reddy PK (1991) Metabolic alterations following continent urinary diversion through colonic segments. *J Urol* 145: 270 –273
- Koch MO, McDougal WS, Thompson CO (1991) Mechanisms of solute transport following urinary diversion through intestinal segments: an experimental study with rats. *J Urol*; 146: 1390–1394
- Kock NG, Nilson AE, Norlen L, Sundin T, Trasti H (1978) Urinary diversion via a continent ileum reservoir: clinical experience. *Scand J Urol Nephrol. Suppl* 49: 23–31
- Kolettis PN, Klein EA, Novick AC et al. (1996) The Le Bag orthotopic urinary diversion. *J Urol* 156: 926 –930
- Koller M, Lorenz W (2002) Quality of life: a deconstruction for clinicians. *J R Soc Med* 95: 48
- Kollias G, Goulandris N, Kastriotis J et al. (1984) Absorbability of mucosa in total replacement of urinary bladder with jejunum: an experimental study. *Urology* 23: 51–54
- Koraitim MM, Atta MA, Foda MK. (1995) Early and late cystometry of detubularized and nondetubularized intestinal neobladders: new observations and physiological correlates. *J Urol* 154: 1700–1702
- Kouhl U, Gerharz E W, Bonfig R, Melekos M, Kable T, Riedmiller H (1996) Ureteral implantation using a serous-lined extramural tunnel (Abol-Enein)-technique of choice in difficult cases. *Eur Urol, suppl* 30: 65
- Kristjansson A, Abol-Enein H, Alm P, Mokhtar A A, Ghoneim M A Mansson W. (1996) Long-term renal morphology and function following enterocystoplasty (refluxing or antireflux anastomosis): an experimental study. *Br J Urol* 78: 840

- 
- Lampel A, Hohenfellner M, Schultz- Lampel D et al. (1995) In situ tunneled bowel flap tubes. 2 new techniques of a continent outlet for Mainz pouch cutaneous diversion. J Urol 53: 308–315
  - Leadbetter Jr GW, Zickerman P, Pierce E (1979) Ureterosigmoidostomy and carcinoma of the colon. J Urol 121(6): 732– 735
  - Leadbetter W F (1951) Consideration of problems incident to performance of uretero-enterostomy: report of a technique. J Urol 65: 818
  - Lee KS, Montie JE, Dunn RL et al. (2003) Hautmann and Studer orthotopic neobladders: a contemporary experience. J Urol 169: 2188 –2191
  - Lee SW, Russell J, Avioli LV (1977) 25-Hydroxycholecalciferol to 1,2 dihydroxycholecalciferol: conversion impaired by systemic metabolic acidosis. Science 195: 994 –996
  - Leibovitch IJ, Ramon J, Chaim JB et al (1991) Increased urinary mucus production: a sequela of cystography following enterocystoplasty. J Urol 145: 736 –737
  - Leissner J, Black P, Fisch M, Hckel M, Hohenfellner R (2000) Colon pouch (Mainz pouch III) for continent urinary diversion after pelvic irradiation. Urology 56-79
  - Leissner J, Fisch M, Hohenfellner R (2006) Colonic pouch (Mainz-pouch III) for continent urinary diversion. BJU Int. Feb 97(2): 417-30
  - Lennon G M, Ryan P C, Fitzpatrick J M (1991) Vergleichende in-vitro- und in-vivo-Versuche am Ureter des Hundes. Akt Urol 22- 193
  - Lindell O, Lehtonen T (1988) Rezidivierende urotheliale Tumoren in einzelnieren mit anschlul eines kolonsegmentes an das nierenbecken. Akt Urol 19 :130-133
  - Lindgren A, Kilander A, Bagge E, Nexø E (1999) Holotranscobalamin - a sensitive marker of cobalamin malabsorption. Eur J Clin Invest, 29: 321
  - Lopez Pereira P, Martinez Urrutia M J, Lobato Romera R, Jaureguizar E (2001) Should we treat vesicoureteral reflux in patients who simultaneously undergo bladder augmentation for neuropathic bladder? J Urol 165: 2259
  - Lorenz W (1989) Methods and instruments for measuring and evaluating quality of life. Langenbecks Arch Chir Suppl II Verh Dtsch Ges Chir 109
-

- 
- Lund F (1980) Cystectomy following full course irradiation. In Pavane-Macaluso M, Smith PH, Edsmyr F. Bladder Tumors and Other Topics in Urological Oncology. New York: Plenum Press: 287
  - Lytton B, and Green DF (1989) Urodynamic studies in patients undergoing bladder replacement surgery. J Urol 141:1394 –1397
  - Magrina J F (1993) Complications of irradiation and radical surgery for gynecologic malignancies. Obstet Gynecol Surv 48: 571–575
  - Maier U, Ehrenbock PM, Hofbauer J (1997) Late urological complications and malignancies after curative radiotherapy for gynecological carcinomas: a retrospective analysis of 10709 patients. J Urol 158: 814–817
  - Makkas M (1910) Zur Behandlung der Blasenektomie. Umwandlung des ausgeschalteten Coecum zur Blase und der Appendix zur Urethra. Zentralblatt für Chirurgie 37:1073-1076
  - Manson W, Colleen S, Sundin T (1984) continent coecal reservoir in urinary diversion. Br J Urol: Aug 56(4): 359-65
  - Mansson W, Colleen S, Low K et al. (1985) Immunoglobulins in urine from patients with ileal and colonic conduits and reservoirs. J Urol 133: 713–716
  - Mansson W, Ahlgren G, White T (1989) Glomerular filtration rate up to 10 years after urinary diversion of different types. Scand. J. Urol. Nephrol 23: 195–200
  - Marriott C (1983) The effect of drugs on the structure and secretion of mucus. Pharmacy Int 4: 320 –323
  - Martinez Sagarra J M, Conde Redondo, Amon Sesmero et al. (2000) Ureteral stenosis of uretero-ileal anastomosis, Actas Urol Esp 24: 375–380
  - McDougal WS (1992) Metabolic complications of urinary intestinal diversion. J Urol 147:1199 –1208
  - McDougal WS (2002) Use of intestinal segments and urinary diversion. In Walsh PC, Retik AB, Vaughan ED Jr, Wein AJ eds, Campbell's Urology, 8th edn, Vol. 4, Chapt. 106. Philadelphia: W.B. Saunders: 3745–3788
  - McDougal WS, Heimbarger S, and Wilmore DW (1978) The effect of exogenous substrate on hepatic metabolism and membrane transport during endotoxemia. Surgery 84: 55– 61
  - McDougal WS, and Koch MO (1989) Effect of sulfate on calcium and magnesium homeostasis following urinary diversion. Kidney Int 35: 105–115
-

- 
- McDougal WS, Koch MO, Shands C III (1988) Bony demineralization following urinary intestinal diversion. *J Urol* 140: 853–855
  - McDougal WS, Stampfer DS, and Kirley S (1995) Intestinal ammonium transport by ammonium and hydrogen exchange. *J Am Coll Surg* 181: 241–248
  - Mesrobian H G, Kelalis P P, Kramer S A (1988) Long-term followup of 103 patients with bladder exstrophy. *J Urol* 139: 719
  - Mills RD, Studer UE (1999) Metabolic consequences of continen urinary diversion. *J Urol* 161:1057–1066
  - Mogg R A (1987) urinary diversion using colon conduit *Br J Urol* 39: 687-692
  - Monti PR, Lara RC, Dutra MA et al. (1997) New technique for construction of efferent conduits based on the Mitrofanoff principle. *Urology* 49 : 112–115
  - Morales P, Golmibu M (1975). Colonic urinary diversion: 10 years experience *J Urol*. Mar 113(39: 302-307
  - Morales, P, Golimbu M (1975) Colonic urinary diversion: 10 years of experience. *J Urol* 113: 302–307
  - Mottaz AE, Zingg EJ, Studer UE (1996) Ureterosigmoidostomy in adults: long term results. *Prog Urol* (Feb) 6(1): 87– 92
  - Mundy AR, and Nurse DE (1992) Calcium balance, growth and skeletal mineralization in patients with cystoplasties. *Br J Urol*; 69:257–259
  - Muraishi O, Ogawa A, Kato H, Okada N (1991) Gastrocystoplasty. *Jpn. J. Urol.*; 82: 1309–1312
  - Murray K, Nurse DE, and Mundy AR (1987) Secreto-motor function of intestinal segments used in lower urinary tract reconstruction. *Br J Urol* 60: 532–535
  - Nasbit RM (1960) Another hopeful look at ureterosigmoid anastomosis. *J Urol* 84: 691
  - Natarajan V, Singh G (2000) Urinary diversion for incontinence in women. *Int Urogynecol J Pelvic Floor Dysfunct* 11: 180–187
  - Naurath H J, Joosten E, Riezler R, Stabler S P, Allen R H, Lindenbaum J (2000) Effects of vitamin B12, folate, and vitamin B6 supplements in elderly people with normal serum vitamin concentrations. *Lancet* 346: 85, 1995. neobladder creation. *J Urol* 163:1108 –1111

- Nelson JH (1969) Atlas of radical pelvic surgery. New York: Appleton century Crofts: 123-139
- Nelson J H (1969) Atlas of Radical Pelvic Surgery, Appleton-Century-Crofts, New York: 181–191
- Niels C, Langkilde, Torsten K, Pless, Finn Lundbeck and Benni Nerstrom (1999) Surgical Repair of Vesicovaginal Fistulae Scand J Urol Nephrol 33: 100–103
- O'Dow J, Robson CN, Matthews JN et al (2001) Reducing mucus production after urinary reconstruction: a prospective randomized trial. J Urol 165:1433–1440
- Orr J D, Shand J E, Watters, D A K, Kirkland I S (1981) Ileal conduit urinary diversion in children: An assessment of the long-term results. Br J Urol 5: 424–427
- Orr J W, Shingleton H M, Hatch K D, Taylor P T, Austin PJ, Eifel C, Levenback J T, Wharton et al.(1995) Time course and incidence of late complications in patients treated with radiation therapy for FIGO stage IB carcinoma of the uterine cervix. Int J Radiat Oncol Biol Phys 32: 1289–1300
- Pagano F (1980) Ureterocolonic anastomosis: description of a technique. J Urol 123: 355
- Pannek J, Senge T (1998) History of urinary diversion. Urol Int 60: 61
- Pantuck, A J, Han, K R, Perrotti M, Weiss R E, Cummings K B (2000) Ureteroenteric anastomosis in continent urinary diversion: long-term results and complications of direct versus nonrefluxing techniques. J Urol, 163: 450.
- Partridge J M, Soong S J (1982) Urinary diversion in patients undergoing pelvic exenteration, Am. J. Obstet. Gynecol 142: 883–889
- Pazooki D, Edlund C, Dahlstrand C, Lindholm E, Tornqvist H, Jonsson O (2005) Continent cutaneous urinary diversion is still a valid alternative after cystectomy for bladder carcinoma. Scand J Urol Nephrol 39: 468
- Pennypacker L C, Allen R H, Kelly J P, Matthews L M, Grigsby J, Kaye K et al. (1992) High prevalence of cobalamin deficiency in elderly outpatients. J Am Geriatr Soc 40: 1197
- Perez C A, Grigsby M A, Lockett et al. (1999) Radiation therapy morbidity in carcinoma of the uterine cervix: dosimetric and clinical correlation. Int J Radiat Oncol Biol Phys 44: 855–866



- Pfitzenmaier J, Loiz J, Faldum A et al. (2003) Metabolic evaluation of 94 patients 5 to 16 years after ileocecal pouch (Mainz Pouch I) continent urinary diversion. *J Urol* 170:1884–1887
- Philipson BM, Kock NG, Jagenburg R et al. (1983) Functional and structural studies of ileal reservoirs used for continent urostomy and ileostomy. *Gut*; 24: 392–398
- Pitts W R, Muecke Jr (1979) 20-year experience with ileal conduits: The fate of the kidneys, *J. Urol*122: 154–157
- Poulsen AL, Overgaard K, Steven K (1997) Bone metabolism following bladder substitution with the ileal urethral Kock reservoir. *Br J Urol* 79:339 – 347
- Ravi R, Dewan A K, Pandey ((1994)) Transverse colon conduit urinary diversion in patients treated with very high dose pelvic irradiation. *Br J Urol* 73: 51–54
- Raz S, Little NA, Juma S (1992) Female urology. In: Walsh PC, Retik AB, Stamey TA, editors. *Campbell's Urology*. 6th ed. Philadelphia: WB Saunders: 2782–828
- Robillard GL, Shapiro AL (1947) Variational anatomy of the middle colic artery. *J Int Coll Surg*: 10:157
- Roth S, Weining C, Hertle L (1996) Continent cutaneous urinary diversion using the full-thickness bowel flap tube as continence mechanism: a simplified tunneling technique. *J Urol* 156: 1922–1925
- Rowland RG, Mitchell ME, Bihle R, Kahnoski RJ, Piser JE (1987) Indiana continent urinary reservoir. *J Urol* 137: 1136–139
- Rowland R (1995) Complications of continent cutaneous reservoirs and neobladders—series using contemporary techniques. *AUA Update Series*, lesson 25, vol. XIV
- Hohenfellner R, Fisch M (2004) *Glenn's Urologic Surgery*, 6th Edition Section IX - Urinary Diversion, Chapter 79 Transverse Colonic Conduit: 223-228
- Rudolf Hohenfellner, Peter Black, Joachim Liessner, Ernst P, Allhof K (2002) refluxing uretrointestinal anastmosis for contienent cutanous urinary diversion. *Journal of urology*. September 168: 1013–1017
- S. Beckley J E, Wajsman J E, Pontes et al. (1982) Transverse colon conduit: a method of urinary diversion after pelvic irradiation. *J Urol* 128: 464–468



- Sadahiro S, Ohmura T, Yamada Y, Saito T, Taki Y (1992) Analysis of length and surface area of each segment of the large intestine according to age, sex, and physique. *Surg Radiol Anat* 14: 251-257
- Sagalowsky AI, Frenkel EP (2002) Cobalamin profiles in patients after urinary diversion. *J Urol* 167:1696 –1700
- Saltzman J R, Russell R M (1998) The aging gut. *Nutritional issues. Gastroenterol Clin North Am* 27: 309
- Santucci RA, Park CH, Mayo ME, et al. (1999) Continence and urodynamic parameters of continent urinary reservoirs: comparison of gastric, ileal, ileocolic, right colon, and sigmoid segments. *Urolog* 54: 252–257
- Savage D G, Lindenbaum J, Stabler S P, Allen R H (1994) Sensitivity of serum methylmalonic acid and total homocysteine determinations for diagnosing cobalamin and folate deficiencies. *Am J Med* 96: 239
- Schlesinger R E, Berman M L, Ballon S C, Lagasse L, Watring W G, Futoran R J, Moore, J G (1979) The choice of an intestinal segment for a urinary conduit, *Surg. Gynecol. Obstet*: 45–48
- Schmidt J D, Buchsbaum DA (1985) Long-term follow-up, further experience and modifications of the transverse colon conduit in urinary tract diversion, *Br J Urol* 57: 284–288
- Schmidt J D, Buchsbaum H J, Jacobo E C (1976) Transverse colon conduit for supravescical urinary tract diversion. *Urology* 8: 542–546
- Schmidt J D, Hawtrey C E, Buchsbaum H J (1975) Transverse colon conduit: A preferred method of urinary diversion for radiation-treated renal malignancies. *J Urol* 113: 308–313
- Sheffner AL (1963) The reduction in vitro in viscosity of mucoprotein solutions by a new mucolytic agent, N-acetyl-L-cysteine. *Ann N Y Acad Sci* 106: 298 –310
- Siklos P, Davie M, Jung RT (1980) Osteomalacia in ureterosigmoidostomy: healing by correction of the acidosis. *Br J Urol* 52: 61-62
- Smith K W, Avis N E, Assmann S F (1999) Distinguishing between quality of life and health status in quality of life research: a meta-analysis. *Qual Life Res* 8: 447

- Soper J T, Berchuk A, Creasman W T, Clarke-Pearson D L (1989) Pelvic exenteration Factors associated with major surgical morbidity. *Gynecol. Oncol.* 35: 93–98
- Sridhar KN, Samuell CT, Woodhouse CR (1983) Absorption of glucose from urinary conduits in diabetics and non-diabetics. *BMJ* 287:1327–1329
- Stabler S P, Lindenbaum J, Allen R H (1997) Vitamin B-12 deficiency in the elderly: current dilemmas. *Am J Clin Nutr* 66: 741
- Stampfer DS, McDougal WS (1997) Inhibition of the sodium/ hydrogen antiport by ammonium ion. *J Urol* 157: 362–363
- Stein JP, Daneshmand S, Dunn M, Garcia M, Lieskovsky G, Skinner DG (2004) Continent right colon reservoir using a cutaneous appendicostomy. *Urology* 63: 577–81
- Stein R, Fisch M, Beetz R (1997) Urinary diversion in children and young adults using the Mainz Pouch I technique. *Br J Urol* 79: 354 –361
- Stein R, Pfitzenmaier J, Behringer M, Hohenfellner R, Thüroff JW (2001) Long-term results (5–16 years) of the Mainz Pouch I technique at a single institution. *J Urol* 165 (Supl.): A360
- Stein R, Schröder A, Hagen T, Thüroff JW (2008) Das Transversum Conduit- Eine Option zur inkontinenten Harnableitung. *Urologe.* 47(Sup. 1): 76
- Stein R, Pfitzenmaier J, Behringer M, Hohenfellner R. Thuroff J (2001) The long-term results (5–16 years) of the Mainz pouch I technique at a single institution. *J Urol, suppl.* 165: 88, abstract 360
- Steiner M S, Morton R A, Marshall F F (1993) Vitamin B12 deficiency in patients with ileocolic neobladders. *J Urol* 149: 255
- Stenzl A, Jarolim L, Coloby P et al. (2001) Urethra-sparing cystectomy and orthotopic urinary diversion in women with malignant pelvic tumors. *Cancer* 92(7): 1864– 1871
- Steven K, Poulsen AL (2000) The orthotopic Kock ileal neobladder: functional results, urodynamic features, complications and survival in 166 men. *J Urol* 164: 288 –295
- Sullivan LD, Chow VD, Ko DSC, Wright JE, McLoughlin MG (1998) An evaluation of quality of life in patients with continent urinary diversions after cystectomy. *Br J Urol* 81: 699–704

- 
- Terai A, Okada Y, Shichiri Y, Kakehi Y, Terachi T, Arai Y et al. (1997) Vitamin B12 deficiency in patients with urinary intestinal diversion. *Int J Urol* 4: 21
  - Thüroff JW, Alken P, Engelman U, Riedmiller H, Jacobi GH, Hohenfellner R (1985). The mainz pouch (mixed augmentation ileum and coecum) for bladder augmentation and continent urinary diversion. *World J Urol* 3: 194-196
  - Thüroff JW, Alken P, Riedmiller H, Engelman U, Jacobi GH, Hohenfellner R (1986) The Mainz pouch (mixed augmentation ileum and cecum) for bladder augmentation and continent diversion. *J Urol* 136: 17–26
  - Tschopp AB, Lippuner K, Jaeger P (1996) No evidence of osteopenia 5 to 8 years after ileal orthotopic bladder substitution. *J Urol* 155: 71–75
  - Übelhör R (1950) Die Darmblase. *Langenbecks Arch Dasch z Chir.* 271:202
  - Unicamp J, Bras U (1993) ureterosigmoid anastomosis: an experimental study in rats. *J Urol* 140: 856–859
  - Varol C, Studer UE. (2004) Managing patients after an ileal orthotopic bladder substitution. *BJU Int* 93: 266 –270
  - Verhoogen J (1908) Neostomie uretero-caecale formation d'une nouvelle poche vesicale et d'un nouvel uretre. *Assoc Fr Urol* 12: 362
  - Waldron-Edward D, and Skoryna SC (1966) The mucolytic activity of amides: a new approach to mucus dispersion. *Can Med Assoc* 94: 1249 –1256
  - Wallace D M (1970): Uretero-ileostomy. *Br J Urol* 42: 529
  - Walsh (1960) Hazards of bladder surgery following irradiation. *J Urol* 84: 627–631
  - Wammack R, Wricke C, Hohenfellner R (2002) Long-term results of ileocecal continent urinary diversion in patients treated with and without previous pelvic irradiation. *J Urol* 167: 2058–2062
  - Webster C R, Bukkapatnam J.D et al. (2003) Continent colonic urinary reservoir (Florida pouch): Long-term surgical complications (greater than 11 years), *J Urol* 169: 174–176
  - Weems D H, Mendenhall W M (1985) Carcinoma of the intact uterine cervix, stage IB-IIA-B, greater than or equal to 6 cm in diameter: irradiation alone vs preoperative irradiation and surgery. *Int J Radiat Oncol Biol Phys* 11: 1911–1914
-

- Wilkin M, Horwitz G, Seetharam A et al. (2005) Long-term complications associated with the Indiana pouch urinary diversion in patients with recurrent gynecologic cancers after high-dose radiation. *Urol Oncol* 23: 12–1
- Williams PL, Warwick R, Dyson M, Bannister LH (1989) *Gray's Anatomy* (37th ed). Edinburgh: Churchill Livingstone: 1774-1787
- Williams RE, Davenport TJ, Burkinshaw L (1967) Changes in whole body potassium associated with uretero-intestinal anastomosis. *Br J Urol* 39: 676–680
- Wilson TG, Moreno JG, Weinberg A, Ahlering TE (1994) Late complications of the modified Indiana pouch. *J Urol* 151: 331–334
- Yakout H, Bissada NK (2003) Intermediate effects of the ileocaecal urinary reservoir (Charleston pouch 1) on serum vitamin B12 concentrations: can vitamin B12 deficiency be prevented? *BJU Int* 91:653– 655
- Yoder I C, Pfister R C (1978) Radiology of colon loop diversion: Anatomical and urodynamic studies of the conduit and ureters in children and adults, *Radiology* 127: 85–92
- Zieman L, Libertino JA (1975) Ileocecal conduit for temporarily and permanent urinary diversion *J Urol* 113: 317-323
- Zoubek J, McGuire EJ, DeLancey JO (1936) The late occurrence of urinary tract damage in patients successfully treated by radiotherapy which have used in uretero-intestinal implantation. *Genitourin Surg* 29: 15
- Zoubek J, McGuire F, Noll R et al. (1989) The late occurrence of urinary tract damage in patients successfully treated by radiotherapy for cervical carcinoma. *J Urol* 141:1347–1349

## 9. Acknowledgments

First and foremost thanks are to **Allah** (God), the most beneficent and merciful.

I would like to thank **Prof. Dr. Margit Fisch**, Prof. of Urology and head of Urology department, University Hospital Hamburg-Eppendorf, who put the idea for this thesis and with her hard efforts it is finished, I will remain indebted to her sincere encouragement and affiliation, she will remain a model of wisdom and patience to me.

I would like to express my thanks to **Prof. Dr. Hassan Abo Elenien**, Prof. of Urology and director of Mansura Urology and Nephrology Center, Egypt for his father-like encouragement and valuable advice.

My deep gratitude is to **Dr. Roland Dahlem**, leader urologist of Urology department, University Hospital Hamburg-Eppendorf for his great help and support, which will never be forgotten.

Special sincere gratitude to **Dr. Sascha Ahyai**, urologist of Urology department, University Hospital Hamburg-Eppendorf for his effort in reviewing this work and for his continuous brother-like love and support.

I would like to thank all members of staff in Urology department, El-Menoufiya Faculty of Medicine, Egypt, members of Urology department ,Asklepios Klinik Harburg ( especially **Dr. Philip Reiß**) and members of Urology department, University Hospital Hamburg- Eppendorf ( especially **Dr. Daniel Pfalzgraf**) for their kind help.

My deep thanks to all **patients**, who are the subject of this study.

Finally, thanks to **my parents** for their continuous support, care and love.

*Khalid Sayed Ahmed*

**10. Curriculum vitae (C.V.)****Personal data:**

- Full name: Khalid Ahmed Mahmoud Sayed Ahmed
- Surname: Sayed Ahmed
- First Name: Khalid Ahmed Mahmoud
- Date of birth: 11.09.1978
- Place of birth: El-Meufeyia, Egypt
- Nationality: Egyptian
- Marital state: Single
- E-Mail: [Khalid\\_sayedahmed@gmx.de](mailto:Khalid_sayedahmed@gmx.de)

**Education and training:****A) School study**

- 1984-1989: Preparatory school
- 1990-1992: Primary school
- 1993-1995: High school
- 1996-1998: Pre-clinical medical study, Menufeyai University, Egypt
- 1997-2001: Clinical medical study, Menufeyai University, Egypt

**B) Qualifications**

- 1995: School-leaving exam(Grade: Excellent)
- December 2001: M.B.B.ch (medical study final exam) Faculty of Medicine Meufeyia University, Egypt (Grade: Excellent)
- April 2006: M.sc. Urology (Magister) Faculty of Medicine Menufeyia University, Egypt (Grade: very good)
- June 2007: First part of PhD-Exam, Menufeyia University, Egypt
- September 2009: Expertise of the Medical Laser applications: University Medical Center Hamburg-Eppendorf, Germany.
- November 2009: First part of European Board of Urology (EBU)
- December 2009: Certified urologist in Medical Syndicate Hamburg, Germany

**Professions and experience:**

- 01.03.2002-28.02.2003: House-Officer (AIP) in Menufeyia University Hospitals, Egypt
- 01.03.2003-16.12.2003: General practice physician in ministry of health Hospitals, Egypt.
- 17.12.2003-18.12.2006: Resident of Urology in Urology dep. Menufeyia University Hospitals, Egypt
- 19.12.2006-28.03.2007: Urologist in Urology dep. Menufeyia University Hospitals, Egypt
- Since 29.03.2007: Assistant-lecturer in Urology department, Faculty of Medicine, Menufeyia University.
- 01.08.2008-30.11.2008: Gest physician (Gastarzt) in Urology department Asklepios Klinik Harburg, Germany.
- Since 01.12.2008: Gest physician (Gastarzt) in Urology department University Hospital Hamburg-Eppendorf, Germany.

---

*Khalid Sayed Ahmed*

## **11. Declaration**

I affirm, that I authored this work independently and unassisted, without use of other sources und helping tools as stated and did not pick up single text passages in form or content.

*Khalid Sayed Ahmed*