Aus der Poliklinik für Mund-, Kiefer- und Gesichtschirurgie

des Kopf- und Neurozentrums-Universitätsklinikum Hamburg-Eppendorf

Direktor: Prof. Dr. Dr. Max Heiland

DISSERTATION

Apicoectomy using Er:YAG laser in association with microscope: a comparative retrospective investigation

zur Erlangung des akademischen Grades

Doctor medicinae dentariae (Dr. med. dent.)

von

Zahnarzt Markus Lietzau

aus Berlin

Hamburg 2013

Angenommen von der Medizinischen Fakultät am: 09.08.2013

Veröffentlicht mit Genehmigung der medizinischen Fakultät der Universität Hamburg

Prüfungsausschuss, der/die Vorsitzende: Prof. Dr. Dr. Max Heiland

Prüfungsausschuss, 2. Gutachter/in: PD Dr. Hartwig Seedorf

1 Publikation

Photomedicine and Laser Surgery
Volume 31, Number 3, 2013

Pp. 1–6
DOI: 10.1089/pho.2012.3393

Apicoectomy Using Er:YAG Laser in Association with Microscope: A Comparative Retrospective Investigation

Markus Lietzau, DDS,[1] Ralf Smeets, MD, DMD, PhD,[2] Henning Hanken, MD, DMD,[2]
Max Heiland, MD, DMD, PhD,[2] and Christian Apel, DDS, PhD[3]

Abstract

Objective: This retrospective clinical investigation intends to examine the effectiveness of an Er:YAG laser used in conjunction with a dental operation microscope for apicoectomy, in comparison with the traditional surgical procedure. ***Background data:*** The Er-YAG laser has shown great potential in application to periapical surgery; however, clinical data are rare. ***Methods:*** To this end, 78 patients who had undergone apicoectomy in a private dental office were selected; 41 patients were treated by the traditional surgical technique for apicoectomy and 37 patients were treated using an Er:YAG laser under microscopic control. The five cardinal symptoms of inflammation were taken as clinical parameters/examination criteria and evaluated after postoperative days 1, 7, and 180, where days 7 and 180 after the operation can be regarded as the customary times for follow-up controls at the private dental office. ***Results:*** Microscopically guided, laser-assisted treatment seems to favor a better healing process overall. After the first postoperative day, redness and swelling of the operation area were significantly reduced ($p<0.001$ and $p=0.0048$). Seven days after the operation, all inflammation parameters were statistically significantly lower in the laser-treated group ($p<0.05$). On day 180, 6 out of 41 patients in the control group still displayed a disturbed function of the treated teeth, whereas none of the patients in the laser group experienced further complaints. ***Conclusions:*** As a result, it can be ascertained that the use of an Er:YAG laser as an adjuvant tool in periapical surgery, with additional control by an operation microscope, displays significantly better results in terms of postoperative healing, in comparison with the conventional surgical treatment of apicoectomy.

Introduction

Since the Er:YAG laser was approved by the United States Food and Drug Administration (FDA) in 1997, this laser wavelength has been put to widespread use in the daily routine of dental offices. Advanced technical developments and ongoing scientific study have steadily expanded the indications for this type of laser. In addition to being used for preparing dental enamel and dentin in caries therapy, there are today also applications for the erbium laser in endodontics. Among the approved indications are root canal debridement and cleaning, and root canal preparation, including enlargement and apicoectomy.[1] The advantages of using a laser in general, and specifically in periapical surgery, are its high precision, less discomfort for the patients as a result of less vibration, bacteria reduction, and a reduced risk of traumatizing surrounding tissue.[2] A biostimulatory effect of Er:YAG laser irradiation is the subject of discussion and is considered to be one of the reasons for more rapid and better healing, for example, in patients with osteonecrosis on bisphosphonate therapy.[3]

Root resection is the therapy of choice, if root-end canal treatment is either not possible or if it fails.[4] The success rate depends upon the experience of the dental surgeon and the technique used.[5] Under optimum conditions, the healing rates are 80–90%.[6] Many different pre-clinical and clinical trials described positive results when using a laser in this field.[7] Based on these data and the advantages of laser application generally described in the literature, the laser is also used for root resection in daily, routine practice. Nevertheless, there is so far no clear evidence that the use of a laser has real advantages in this indication. There are no results from controlled clinical trials or recommendations from scientific societies.

The aim of the present investigation was to compare the success of laser-assisted root resection with that of the conventional surgical method. Clinical cases from the daily

[1]Private Dental Office for Implantology, Laser Dentistry and Endodontology, Casa Dentalis am Schlachtensee, Berlin, Germany.
[2]Department of Oral and Maxillofacial Surgery, University Medical Center, Hamburg-Eppendorf, Hamburg, Germany.
[3]Department for Conservative Dentistry, Periodontology and Preventive Dentistry, RWTH Aachen University, Aachen, Germany.

routine of a private dental office specializing in oral surgery were examined retrospectively to this end.

Materials and Methods

The study population consisted of a total of 78 patients undergoing apicoectomy in a private dental office between October 2009 and October 2011. The medical records of all patients who matched the criteria described here were selected for the retrospective investigation. Prior to the start of treatment, all patients were free to choose whether the laser was to be used as adjuvant therapy. It should be noted that use of the laser in the private office entailed additional costs for the patient. Consequently, the cost factor was very often the reason for deciding on one therapy or the other. Informed consent was obtained from all patients before treatment. Retrospective analysis of the data was according to the guidelines of the Helsinki Declaration of the World Medical Association (2008).

Clinical and radiological examinations indicated at least one tooth requiring apicoectomy.

The inclusion criteria were:

- Age ≥ 18 years
- Not pregnant
- Not suffering from any serious general complaints
- Having an indication for apicoectomy with retrograde preparation of the root canal

The indication for periapical surgery existed:

- In the event of persistent apical periodontitis with clinical symptoms, or increasing, radiological osteolysis following complete or partial root canal filling or re-treatment, if this could not be removed or improved, or only by taking unreasonable risks (e.g., in patients with complex dentures and particularly with retention pins)
- Following root canal filling with overfilled root canal cement and clinical symptoms
- If conservative root treatment was not feasible, or in the event of substantial morphological variation of the roots that prevented complete root canal filling
- In the event of teeth with obliterated root canals that were no longer accessible with instruments, together with clinical and/or radiological symptoms
- If an apical lesion >5 mm was present
- In cases of persistent apical periodontitis, as an alternative to conservative endodontic re-treatment, if this was rejected by the patient

For the purpose of the present study, all groups of teeth (incisors, canines, premolars and molars) with one, two, and three roots were included.

Root apices of a total of 37 teeth were resected by Er:YAG laser treatment under an operation microscope (method 1: laser with microscope), and 41 teeth were treated by the traditional surgical procedure (hereinafter referred to as method 2), described subsequently.

All treatments were performed in a private dental office by the same dental surgeon, who had many years of clinical experience.

Surgical procedure

All apicoectomies were performed with the patient under local anesthetic. After the application of surface anesthesia with Xylocain® Pumpspray dental (Astra Zeneca GmbH, Wedel, Germany), either an infiltration and/or a block anesthetic was administered using Ultracain® D-S (Sanofi Aventis, Berlin, Germany), depending upon the location of the tooth involved.

A local anesthetic without vasoconstrictors (Ultracain D®, Sanofi Aventis, Berlin, Germany) was administered to those patients with a contraindication for the use of adrenalin. A waiting time of at least 10 min was observed, until the local anesthetic took effect. After adjustment and alignment of the ProErgo dental operation microscope (Carl Zeiss, Jena, Germany), treatment was started and then performed solely under the microscope.

A semicircular vestibular Partsch's incision was performed in all patients. The initial incision was made using a 15c scalpel blade (Martin, Tuttlingen, Germany) in the vestibule area of the tooth involved. Thereafter, a mucoperiosteum flap was prepared with a periosteal elevator (Martin, Tuttlingen, Germany). The root apex was detected by following the tooth axis toward the apex. In some cases, the apical cortical bone was already disintegrated by osteolytic decay, so that only a little osseous preparation was necessary. In the cases in which teeth still displayed an intact apical cortical bone, the defect was exposed using a round burr (Brasseler Komet, Lemgo, Germany). After presentation of the osseous defect, resection of the root apex involved was undertaken, along with simultaneous removal of the pathological tissue. The root apex concerned was ablated using the Er:YAG laser. To this end, the laser system (KEY Laser 3^+, KaVo, Biberach, Germany) was set to an energy of 450 mJ and a repetition rate of 6 Hz. The 2060 handpiece was used in focused mode (spot size of 0.63 mm) for this treatment, under cooling with a continuous air/water mist (1 mL/min). The settings used resulted in a fluence of 145 J/cm^2. The osseous defect was subsequently "decontaminated" with the laser, using the same settings mentioned, but in defocused mode (target distance $\sim$15 mm).

Thereafter, retrograde preparation of the root canal was performed, up to 3 mm toward the crown, using ultrasonic equipment (Sirona, Bensheim, Germany) fitted with special attachments. A special zinc oxide-eugenol cement (Hermetic®, lege artis Pharma GmbH, Dettenhausen, Germany) was used for retrograde filling of the root canal.

After the cement had entirely cured, the area of the osseous defect was debrided with a sharp curette until bleeding occurred. Concluding wound closure was performed by means of individual button sutures, using Silon monothread suture material of size 5.0 (Chirmax, Prague, Czech Republic).

In the control group, apicoectomy was performed according to the same guidelines, but without using an operation microscope or a laser. Here, the root apex was removed using a Lindemann burr.

All patients were instructed, both orally and in a written instruction sheet, to refrain from cleaning their teeth on the day of dental treatment, in order to avoid trauma in the area. Between days 2 and 7, the teeth were to be cleaned only with a toothbrush. In addition, rinsing was prescribed after cleaning the teeth in the morning and evening, using a mouthwash of chlorhexidine digluconate 0.2% rinsing solution (GlaxoSmithKline, Buehl, Germany).

Postoperative examinations

The follow-up controls were geared to the standard procedure in the private dental office. The patients first came for an examination 1 day after the operation. The stitches were removed after 7 days, at which time a postoperative assessment was also made. In the absence of complaints, the follow-up control to confirm the success of root resection is customarily performed after a period of 6 months (180 days).

An radiographic control was performed immediately after apicoectomy. Depending upon the location of the tooth and the tolerance of the patient, this involved individual digital images or half-side shots, which were taken with a Sirona Heliodent plus or Orthophos XG 3 X-ray device (Sirona, Bensheim, Germany).

As described, patients were examined on postoperative days 1, 7, and 180. The clinical examination included a visual check of the operated area, as well as of the structures adjacent to it. A palpatory examination was also performed. A decision (positive [1] and negative [0]) was made regarding the occurrence of the relative criteria/parameters described subsequently.

Definition of the criteria/examination parameters

Redness, heat, pain, swelling, and disturbed function in the operation area were considered as the cardinal signs of inflammation.

Redness extending 2 mm around the incision was rated as a positive result. The parameter *heat* was documented as positive if the patients and the treating dental surgeon considered the operated area, together with the adjacent structures, to have an elevated temperature. Regarding the parameter *pain*, a positive result was defined as a sensation of pain at rest, without any external mechanical, manual, or chemical interference. The parameter *swelling* was considered positive if swelling of ≥ 2 mm was both visually and palpably detectable. Thereafter, the parameter *disturbed function* was documented as positive if a patient indicated speech, facial, and/or masticatory restrictions. Specifically, this parameter was rated as positive after 180 days if the patient stated, for example, that the tooth could not be used properly, or if other abnormal sensations were reported.

Statistical evaluation

The statistical investigation was restricted primarily to verification of the contingency tables, with the alternatives of affiliation to a group and (non-)incidence of inflammation parameters, by means of a χ^2 test and a significance test using Fisher's exact test. As the hypothesis was formulated in favor of the laser/microscope treatment, only such a one sided test result is cited. The calculations were performed with SPSS 17.0 software.

Results

After the first postoperative day, overall inflammation in all patients in the group treated with laser therapy was less. Nevertheless, only two of the parameters showed a statistically significant difference. Redness and swelling of the operation area were less in the laser-irradiated patients ($p < 0.001$ and $p = 0.048$, Table 1).

Table 1. The Incidence of Inflammation Parameters After the 1st Postoperative Day

After 1st day	*Control group*	*Laser treatment*	*Test statistic χ^2*	*Fisher's exact test Sig. 1 sided*
Patients	41	37		
Inflammation parameters				
Redness				
Patients	20	4	13.163	**0.000**
% within group	48.8%	10.8%		
Pain				
Patients	31	21	3.111	0.064
in % of group	75.6%	56.8%		
Heat				
Patients	5	1	2.468	0.125
% within group	12.2%	2.7%		
Swelling				
Patients	22	12	3.564	**0.048**
% within Group	53.7%	32.4%		
Disturbed function				
Patients	21	16	0.496	0.317
% within group	51.2%	43.2%		

Bold signifies statistically significant differences.

On Day 7, hardly any symptoms were ascertained in the patients treated by laser. All investigated parameters were statistically significantly lower in the laser-treated group ($p < 0.05$, Table 2).

Both groups no longer showed any signs of acute inflammation after 180 days. Only the *disturbed function* parameter was given a positive rating by 6 of the 41 patients in the control group. No further complaints were experienced

Table 2. The Incidence of Inflammation Parameters After the 7th Postoperative Day

After 7th day	*Control group*	*Laser treatment*	*Test statistic χ^2*	*Fisher's exact test Sig. 1 sided*
Patients	41	35		
Inflammation parameters				
Redness				
Patients	8	0	7.633	**0.005**
% within group	19.5%	0.0%		
Pain				
Patients	11	1	8.161	**0.004**
% within group	26.8%	2.9%		
Heat				
Patients	7	0	6.582	**0.010**
% within group	17.1%	0.0%		
Swelling				
Patients	9	0	8.715	**0.002**
% within group	22.0%	0.0%		
Disturbed function				
Patients	10	1	7.072	**0.007**
% within group	24.4%	2.9%		

Bold signifies statistically significant differences.

Table 3. The Incidence of Inflammatory Parameters 180 Days After Treatment

After 180th day	*Control group*	*Laser treatment*	*Test statistic* χ^2	*Fisher's exact test Sig. 1 sided*
Patients	41	35		
Disturbed function				
Patients	6	0	5.561	**0.021**
% within group	14.6%	0.0%		

Bold signifies statistically significant differences.

in the group of patients treated by laser. This result was also statistically significant ($p = 0.021$, Table 3).

If it is assumed that the assessment of the type of treatment is less relevant as regards specific inflammation symptoms, it would seem acceptable to subsume them into an index and thus evaluate their quantities and/or frequency and means. On the basis of this condensed information, a significant difference between the combined laser/microscope treatment and the control group can be detected in the follow-up control, even after the first postoperative day (Fig. 1).

Discussion

The present investigation had the objective of examining the effectiveness of using an Er:YAG laser in combination with a dental OP microscope for endodontic surgery. Therefore, we retrospectively selected the medical records of patients who had undergone apicoectomy in a private dental office. Two groups were compared – combined laser/microscope treatment versus conventional treatment – with the first group representing the "most modern" technique.

The choice of laser was made by referring to earlier studies, which were able to show less thermal destruction and carbonization of tissue after treatment with an Er:YAG laser, in comparison with other lasers. [2,8] This is attributable, on the one hand, to its water cooling feature and, on the other hand, to the "thermomechanical" ablation process of the Er:YAG laser.[9] Atalay et al. moreover confirm that use of a laser offers increased benefits in oral, dental and surgical therapy.[10]

In the case of apicoectomies in particular, the Er:YAG laser performs better ablations than the Ho:YAG laser, for example. A smoother and cleaner surface in the resection area was achieved without thermal damage.[11] Furthermore, Zhao et al. were able to demonstrate the superiority of the Er:YAG laser for apicoectomy in comparison with ultrasound and rotating-diamond instruments. The resultant reduction in postoperative complaints, as well as improved wound healing, was confirmed in this study.[12] Takeda et al. and Angiero et al. likewise show in their clinical studies that use of the Er:YAG laser leads to high success rates in root resection.[13,14] However, no control groups were examined in either of the studies.

The exact reasons for the described beneficial effects of Er:YAG laser irradiation in periapical surgery are not yet known. A biostimulatory effect and "disinfection" of the operation area by Er:YAG laser irradiation are the subject of discussion, and perhaps promote early healing.[3] Furthermore, it has been shown in an animal model that Er:YAG laser irradiation seems to stimulate platelet-derived growth factor secretion and, therefore, enhances the healing of osteotomy sites.[15] Aleksic et al. demonstrated *in vitro* that low-level Er:YAG laser irradiation enhances osteoblast proliferation through activation of the mitogen-activated protein kinase (MAPK)/extracellular signal regulated kinase (ERK) pathway. They suggest that Er:YAG laser irradiation is, perhaps, able to promote healing in periodontal or implant sites.[16]

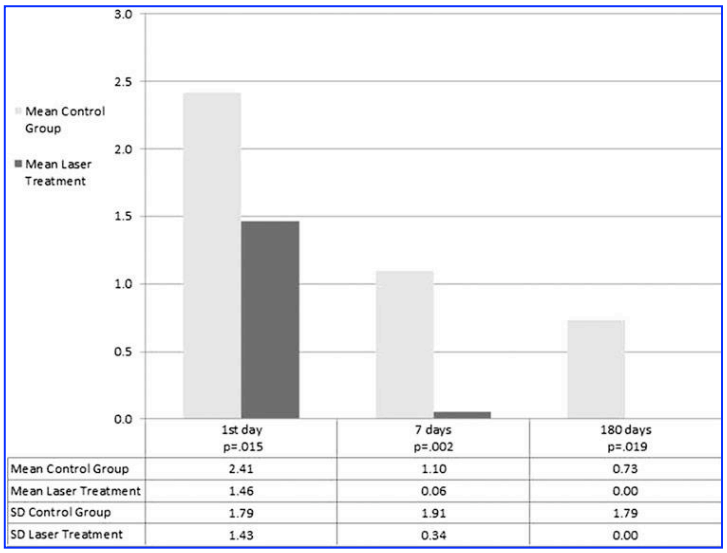

FIG. 1. Mean inflammation index for laser treatment and control group according to postoperative days. The table contains standard deviations. The groups are statistically significantly different for the whole observation period ($p < 0.05$)

A conventional surgical approach, using a scalpel and a rotating burr, was used in all patients in the present investigation. This was because laser incisions are generally considered to show slightly delayed healing because of thermal destruction of the tissue.[17,18] Even though the erbium laser causes the lowest thermal increase in soft tissue, there is so far no clear evidence of advantages of using lasers for this application.[19] The Er:YAG laser seems well suited to the ablation of bone. Temperature increase during Er:YAG laser ostectomies is very low, and thermal alterations are minimal.[20,21] From an animal model comparing Er:YAG laser and burr, Martins et al. reported a thin layer of thermal damage and slightly reduced bone healing.[21] Therefore, we decided to use the Er:YAG laser in the laser cohort only for root resection and "disinfection" of the osseous defect.

In this regard, statistically significantly better wound healing, compared with the control group, was ascertained for the examination parameters of *redness* and *swelling*, even after the first postoperative day in the present investigation. This observation was made for all five inflammation parameters after day 7. There was only one patient positive for the parameters *pain* and *disturbed function*. The success of performing apicoectomy with an Er:YAG laser in conjunction with an OP microscope is, therefore, clearly apparent after 180 days. In this respect, no further complaints were detected in any patient of the laser-treated group during the concluding control examination.

Furthermore, numerous studies have shown a lower postoperative pattern of discomfort, even in periodontal therapies, in patients treated by Er:YAG lasers.[22] Even as far back as 1994, Aoki et al. had already shown that effective removal of subgingival plaque is possible by employing power densities of 10.6 J/cm^2 in the contact mode.[23] Furthermore, the efficacy of Er:YAG lasers as regards removal of debris and smear layers from the root canal walls has been confirmed in previous studies.[24] More recent studies show some positive onward developments of the laser systems, such as an innovative diode-pumped Er:YAG laser, which may represent a real alternative to currently familiar laser systems.[25]

Another allegedly helpful aspect is the introduction and employment of the operation microscope, which Carr and Murgel described as a revolution in endodontics, as well as in apicoectomy.[26] The advantage of using magnification devices is, however, the subject of critical debate.[27,28] Nevertheless, the microdentistry and microsurgical approach seems to permit predictable success in the healing of endodontic lesions.[6]

Conclusions

In summary, the results of the present study reveal a correlation with the laser studies previously described. However, the question arises as to whether the significantly better results in this study were achieved only by employing both laser and microscope, or whether comparable results would have been equally possible using only one of these resources. For example, this could in turn be broken down into percentages indicating the contributions to success apparently made by the Er:YAG laser and by the operation microscope, in comparison with traditional apicoectomy.

Furthermore, we also need to mention the disadvantages of retrospective studies compared with prospective studies. Selection bias, information, and concealment bias cannot be completely ruled out.

The question should also be asked as to whether the patients felt a subjectively positive effect because of the use of "modern" technical equipment for treatment, without this being classed as scientifically significant objectivity. The patient satisfaction rate is usually extremely high when using lasers.[29]

In the future, it will, therefore, definitely be possible to exploit the benefits of using Er:YAG lasers with the assistance of operation microscopes for apicoectomies in everyday practical dentistry.

However, this approach to the abovementioned differentiation between microscope-laser therapy and a variety of other treatment methods should be further verified by means of additional clinical research.

Author Disclosure Statement

No competing financial interests exist.

References

1. American Dental Association (2009). Statement on Lasers in Dentistry: ADA Council on Scientific Affairs. Available at: http://www.ada.org/1860.aspx
2. Komori, T., Yokoyama, K., Takato, T., and Matsumoto, K. (1997). Clinical application of the erbium:YAG laser for apicoectomy. J. Endod. 23, 748–750.
3. Vescovi, P., Manfredi, M., Mergio E., Meleti, M., Fornaini, C., Rocca J.P., and Nammour, S. (2010). Surgical approach with Er:YAG laser on osteonecrosis of the jaws (ONJ) in patients under bisphosphonate therapy (BPT). Lasers Med. Sci. 25, 101–113.
4. Cohn, S.A. (1998). When all else fails…Aust. Endod. J. 24, 128–129.
5. Setzer, F.C., Shah, S.B., Kohli, M.R., Karabucak B., and Kim S. (2010). Outcome of endodontic surgery: a meta-analysis of the literature – Part 1: Comparison of traditional root-end surgery and endodontic microsurgery. J. Endod 36, 1757–1765.
6. v. Arx, T. (2005). Failed root canals: the case for apicoectomy (periradicular surgery). J. Oral Maxillofac. Surg. 63, 832–837.
7. Mohammadi, Z. (2009). Laser applications in endodontics: an update review. Int. Dent. J. 59, 35–46.
8. Paghdiwala, A.F. (1993). Root resection of endodontically treated teeth by erbium:YAG laser radiation. J. Endod. 19, 91–94.
9. Hibst, R., and Keller, U. (1989). Experimental studies of the application of the Er:YAG laser on dental hard substances: I. Measurement of the ablation rate. Lasers Surg. Med. 9, 338–344.
10. Atalay, B., Yalcin, S., Emes, Y., et al. (2011). Bisphosphonate-related osteonecrosis: laser-assisted surgical treatment or conventional surgery? Lasers Med. Sci. 26, 815–823.
11. Komori, T., Yokoyama, K., Matsumoto, Y., and Matsumoto, K. (1997). Erbium:YAG and holmium:YAG laser root resection of extracted human teeth. J. Clin. Laser Med. Surg. 15, 9–13.
12. Zhao, X.Y., Wang, S.M., and Zhang, C.F. (2010). Root resection by Er:YAG laser: a scanning electron microscope study. Hua Xi Kou Qiang Yi Xue Za Zhi 28, 526–528.
13. Takeda, A., Anjo, T., Takashina, M., Ebihara, A., and Suda, H. (2003). Apicoectomy using Er:YAG laser – a clinical study. ISC 1248, 261–263; doi: 10.106/S0531-5131(02)01291-8.
14. Angiero, F., Benedicenti, S., Signore, A., Parker, S., and Crippa, R. (2011). Apicoectomies with the Erbium Laser: a

complementary technique for retrograde endodontic treatment. Photomed. Laser Surg. 29, 845–849.
15. Kesler, G., Shvero, D.K., Tov, Y.S, and Romanos, G. (2011). Platelet derived growth factor secretion and bone healing after Er:YAG laser bone irradiation. J. Oral Implantol. 37, 195–204.
16. Aleksic, V., Aoki, A., Iwasaki, K., Takasaki, A.A., Wang, C.Y., Abiko, Y., Ishikawa, I., and Izumi, Y. (2012). Low-level Er:YAG laser irradiation enhances osteoblast proliferation through activation of MAPK/ERK. Lasers Med. Sci. 25, 559–569.
17. Luomanen, M., and Meurmann, J.H. (1986). Laser-induced alterations in rat oral mucosa. Scand. J. Dent. Res. 94, 452–460.
18. Jin, J.Y., Lee, S.H., and Yoon, H.J. (2010). A comparative study of wound healing following incision with a scalpel, diode laser or Er,Cr:YSGG laser in guinea pig oral mucosa: A histological and immunohistochemical analysis. Acta Odontol. Scand. 68, 232–238.
19. Merigo, E., Clini, F., Fornaini, C., et. al. (2012). Laser-assisted surgery with different wavelength: a preliminary ex vivo study on thermal increase and histological evaluation. Lasers Med Sci; doi: 10.1007/s10103-012-1081-8.
20. Pandurić, D.G., Bago, I. Katanec, D., Zabkar, J. Miletić, I., and Anić, I. (2012). Comparison of Er:YAG laser and surgical drill for osteotomy in oral surgery: An experimental study. J. Oral Maxillofac. Surg. 70, 2515–2521.
21. Martins, G.L., Puricelli, E., Baraldi, C.E., and Pononi, D. (2011). Bone healing after bur and Er:YAG laser ostectomies. J. Oral Maxillofac. Surg. 69, 1214–1220.
22. Rotundo, R., Nieri, M., Cairo F., et al. (2010). Lack of adjunctive benefit of Er:YAG laser in non-surgical periodontal treatment: a randomized split-mouth clinical trial. J. Clin. Periodontol. 37, 526–533.
23. Aoki, A., Ando, Y., Watanabe, H., and Ishikawa, I. (1994). In vitro studies on laser scaling of subgingival calculus with an erbium:YAG laser. J Periodontol. 65, 1097–1106.
24. Takeda, F.H., Harashima, T., Kimura, Y., and Matsumoto, K. (1998). Efficacy of Er:YAG laser irradiation in removing debris and smear layer on root canal walls. J. Endod. 24, 548–551.
25. Stock, K., Hausladen, F., and Hibst, R. (2012). Investigation on the potential of a novel diode pumped Er:YAG laser system for dental applications. Proc. SPIE. 8208, 82080D-82080D-7.
26. Carr, G.B., and Murgel, C.A.F. (2010). The use of the operating microscope in endodontics. Dent. Clin. N. Am. 54, 191–214.
27. Del Fabbro, M., and Taschieri, S. (2010). Endodontic therapy using magnification devices: a systematic review. J. Dent. 38, 269–275.
28. Setzer, F.C., Kohli, M.R., Shah, S.B., Karabucak, B., and Kim, S. (2012). Outcome of endodontic surgery: a meta-analysis of the literature – Part 2: Comparison of endodontic microsurgical techniques with and without the use of higher magnification. J. Endod. 38, 1–10.
29. Fornaini, C., Riceputi, L.L.-P., and Rocca J.P. (2012). Patient responses to Er:YAG laser when used for conservative dentistry. Lasers Med. Sci. 27, 1143–1149.

Address correspondence to:
Markus Lietzau
Breisgauer Strasse 1-3
D-14129 Berlin
Germany

E-mail: ml@casadentalis-schlachtensee.de

2 Darstellung der Publikation

Der Er:YAG Laser hat großes Potential in der Anwendung bei der Wurzelspitzenresektion gezeigt, allerdings gibt es hierzu nur wenige klinische Daten. Ziel der retrospektiven Untersuchung war es, die Effektivität eines Er:YAG Lasers unter Benutzung eines dentalen Mikroskopes bei der Wurzelspitzenresektion im Vergleich zur herkömmlichen chirurgischen Technik zu untersuchen. Auf Basis der vorliegenden Ergebnisse wäre es denkbar, weiterführende klinische Studien durchzuführen, um die hier beschriebene Technik der Wurzelspitzenresektion als Goldstandard festlegen zu können.

Zu diesem Zweck wurden 78 Patientenfälle ausgewählt, bei denen eine Wurzelspitzenresektion in einer privaten zahnmedizinischen Praxis durchgeführt wurde. Bei 41 Patienten kam die traditionelle chirurgische Technik der Wurzelspitzenresektion zur Anwendung und bei 37 Patienten wurde ein Er:YAG Laser unter mikroskopischer Kontrolle eingesetzt. Die fünf klassischen Entzündungsparameter wurden als Untersuchungskriterien herangezogen und nach den postoperativen Tagen 1, 7 und 180 erhoben, wobei Tag 7 und 180 als die üblichen Zeiten für Anschlusskontrollen in der zahnmedizinischen Praxis angesehen werden. Durch die mikroskopisch geführte, laser-unterstützte Behandlung scheint eine bessere Heilung erzielt werden zu können. Nach dem ersten postoperativen Tag konnte eine signifikant geringere Rötung und Schwellung des Operationsgebietes beobachtet werden ($p = 0.001$ und $p = 0.0048$). Sieben Tage nach dem Eingriff waren alle Entzündungsparameter in der Lasergruppe statistisch signifikant geringer, als in der Vergleichsgruppe ($p < 0.05$). Am Tag 180 zeigten

immer noch 6 der 41 Patienten der Kontrollgruppe eine eingeschränkte Funktionalität des operierten Zahnes während die Patienten der Lasergruppe keine weiteren Beeinträchtigungen aufwiesen.

Zusammenfassend lässt sich feststellen, dass die Wurzelspitzenresektion unter Anwendung eines Er:YAG Lasers und unter mikroskopischer Kontrolle im Vergleich zur traditionellen Technik deutlich bessere Ergebnisse hinsichtlich der postoperativen Heilung des Wundgebietes erzielt.

Die Vorteile der Laserbenutzung im Allgemeinen, aber auch im Speziellen in der Wurzelspitzenresektion sind die hohe Präzision, geringere Vibration und dadurch höherer Komfort der Behandlung, bakterielle Reduktion und ein geringeres Risiko umliegendes Gewebe zu schädigen[1]. Ein biostimmulierender Effekt des Er:YAG Lasers ist der Inhalt aktueller Diskussionen und wird als entscheidender Faktor für die bessere Wundheilung, z.B. bei Patienten mit Osteonekrose bei Bisphosphonattherapie angenommen[2].

Die Wurzelspitzenresektion ist das Mittel der Wahl bei missglückten oder nicht durchführbaren orthograd angestrebten endodontischen Behandlungen[3]. Die Erfolgsrate ist abhängig von der Erfahrung des Behandlers und der angewendeten Technik[4]. Unter optimalen Bedingungen liegt die Erfolgsquote bei 80-90%[5]. Viele verschiedene vorklinische und klinische Studien zeigen einen positiven Verlauf bei Benutzung eines Lasers[6]. Nichtsdestotrotz ist keine eindeutige Evidenz der Laserbenutzung in dieser Indikation vorhanden. Es gibt keine Ergebnisse aus kontrollierten Studien, oder Stellungnahmen wissenschaftlicher Organisationen. Ziel dieser Studie war es daher die laser-unterstützte Behandlung mit der konventionellen Technik zu vergleichen. Hierfür wurden klinische Fälle aus einer oralchirurgisch spezialisierten Praxis retrospektiv ausgewertet.

Die Population der Studie beinhaltet im Gesamten 78 Patienten die einer Wurzelspitzenresektion in einer privaten Praxis zwischen Oktober 2009 und Oktober 2011 unterzogen wurden. Die aufgezeichneten Daten mit folgend aufgeführten Kriterien wurden gesammelt und retrospektiv ausgewertet. Am Anfang jeder Behandlung wurde den Patienten freigestellt, ob sie die konventionelle oder die laser-gestützte Therapie bevorzugen. Es sollte angemerkt werden, dass die Laserbehandlung mit Zusatzkosten für den Patienten verbunden war. Der Kostenfaktor war des Öfteren der Grund für die Entscheidung des Patienten für die konventionelle Therapie. Vor der Behandlung erfolgte eine ausführliche Aufklärung jedes Patienten. Die retrospektive Analyse der Daten wurde streng nach den Gesichtspunkten der Helsinki Deklaration (2008) durchgeführt.

In der vorliegenden Studie fiel die Wahl auf den Er:YAG Laser, der geringere Carbonisierung und thermale Schädigung des zu behandelnden Gebietes in vorangegangenen Studien zeigte [7, 1]. Dies hat auf der einen Seite mit der entsprechenden Wasserkühlung, auf der anderen Seite mit dem Er:YAG Laser typischen Ablationsprozesses zu tun[8].

Im speziellen Falle der Wurzelspitzenresektion zeigte beispielsweise der Er:YAG Laser bessere Werte bezüglich der Ablation im Vergleich zu dem Ho:YAG (holmium:YAG) Laser. Weiterhin lässt sich eine glattere und sauberere Oberfläche der abgetragenen Wurzelspitze ohne thermische Schädigung feststellen[9]. Außerdem konnten Zhao et al. (2010) die Vorteile des Er:YAG Lasers gegenüber dem rotierenden und ultraschall betriebenem Abtrag der Wurzelspitze zeigen. Die daraus resultierende Reduktion der postoperativen Komplikationen sowie eine bessere Wundheilung konnten in dieser Studie gezeigt werden[10]. Takeda et al. (2003) und Angiero et al. (2011) konnten in ihren klinischen Studien belegen, dass der Er:YAG

Laser in der Wurzelspitzenresektion zu höheren Erfolgsraten führt[11, 12]. Allerdings sind hier keine Kontrollgruppen zum Vergleich angeführt worden.

Die genauen Gründe für die bessere Wundheilung der apikalen Region und Umgebung sind bis zum heutigen Zeitpunkt nicht genau zu benennen. Ein biostimmuliernder Effekt und die 'Desinfektion' durch den Er:YAG Laser sind derzeit Inhalt verschiedener Diskussionen[2.] Weiterhin wurde im Tierversuch gezeigt, dass der Er:YAG Laser eine stimulierende Wirkung auf den 'platelet derieved growth factor' hat und somit eine bessere Wundheilung nach Osteotomie erreicht werden kann[13]. Aleksic et al. demonstrierten in vitro, dass der niedrig dosierte Er:YAG Laser eine Proliferation von Osteoblasten durch Aktivierung des MAPK/ERK Signalübertragungsweges induzierte. Die Autoren vermuten, dass die Applikation von dem Er:YAG Laser eine bessere Heilung von paradontal geschädigtem oder an Implantaten pathologisch verändertem Gewebe erreichen lässt[14].

Eine konventionelle Eröffnung mit Skalpell und initial benutztem rotierendem Bohrer wurde an allen Patienten dieser Studie verwendet. Dies ist der Tatsache geschuldet, das eine Inzision mit Laser eine höhere thermale Schädigung und somit eine verzögerte Wundheilung des Gebietes zur Folge hat[15, 16]. Auch wenn der Er:YAG Laser die geringste Schädigung im mukosalen Bereich erreicht, ist keine eindeutige vorteilhafte Beschreibung für diese Indikation vorhanden[17]. Der Er:YAG Laser scheint für den knöchernen Abtrag indiziert zu sein. Die Temperaturentwicklung ist niedrig und die thermischen Schäden minimal[18, 19]. Im Vergleich des Er:YAG Lasers zu einem rotierenden Bohrer im Tiermodel konnten Martins et al. zeigen, dass eine dünne Schicht thermaler Schädigung und eine leicht reduzierte Knochenheilung existent ist[19]. Aus diesem Grund entschieden wir uns dafür, die Laseranwendung in der Lasergruppe nur für die Resektion an sich und für die 'Desinfektion' des knöchernen Defektes zu etablieren. In diesem Zusammenhang ließ sich eine

statistisch signifikant bessere Wundheilung im Vergleich zur Kontrollgruppe nach dem ersten postoperativen Tag bezüglich der Parameter ‘Rubor’ und ‘Tumor’ feststellen. Diese Beobachtung ließ sich für alle fünf Parameter nach sieben Tagen post- OP fetstellen. Es gab lediglich einen Patienten mit den positiven Parametern ‘Dolor’ und ‘functio laesa’. Der Vorteil der Resektion der Wurzelspitze mit einem Laser unter mikroskopischer Kontrolle ist nach 180 Tagen klar zu erkennen. Nach dieser Zeit ist keiner der in der Lasergruppe behandelten Patienten als positiv in einem oder mehreren der Parameter vermerkt worden.

Weiterhin zeigen mehrere Studien einen geringeren Diskomfort in der Behandlung mit einem Er:YAG Laser, ebenso in der parodontalen Therapie[20]. Bereits 1994 zeigten Aoki et al. das effektive Entfernen von subgingivalen Konkrementen bei einer Einstellung von 10.6 J/cm^2 im Kontaktmodus[21]. Außerdem konnte der effektive Abtrag von Debris in Kanalwänden durch den Er:YAG Laser in verschieden Studien bewiesen werden[22]. Fortwährende Studien untersuchen die positiven Effekte von neu entwickelten Lasersystemen, wie zum Beispiel dem innovativen Dioden- Pump Er:YAG Laser[23].

Ein weiteres hilfreiches Instrument ist die Anwendung eines Operationsmikroskopes, welches Carr and Murgel (2010) als eine Revolution sowohl in der orthograden, als auch in der chirurgischen Endodontie bezeichneten[24]. Der Vorteil der Vergrößerungshilfen ist Gegenstand kritischer Diskussionen[25, 26]. Nichtsdestotrotz scheint die mikrodentale und mikrochirurgische Vorgehensweise einen positiven Effekt auf die Heilung endodontischer Läsionen zu haben[5].

Abschließend stellt sich die Frage, ob die bessere Wundheilung nur in der kombinierten Anwendung von Laser und Mikroskop entsteht, oder ob nur eines der verwendeten Hilfsmittel ähnlich gute Untersuchungsergebnisse zulassen würde.

Weiterhin sollten die Nachteile einer retrospektiven Studie kritisch bewertet und mit den Ergebnissen einer prospektiven Studie verglichen werden. Die Befangenheit in der Auswahl, der Informationsauswertung und der Verschwiegenheit konnten nicht komplett ausgeräumt werden.

Außerdem muss hinterfragt werden, ob die Patienten aufgrund einer 'modernen Therapie' einen positiven Effekt empfunden haben. Die Patientenzufriedenheit ist sehr hoch, wenn ein Laser seine Anwendung findet[27].

In der Zukunft wird es möglich sein, in der routinemäßigen Behandlung die Vorteile von Er:YAG Laser und Operationsmikroskop noch weiter auszuwerten.

Weitere Studien zur Untersuchung der mikroskopisch unterstützten, lasergeführten Wurzelspitzenresektion im Vergleich zu anderen Methoden sollten zukünftig durchgeführt werden.

Literaturübersicht

1 Komori, T., Yokoyama, K., Takato, T., Matsumoto, K. (1997). Clinical application of the erbium:YAG laser for apicoectomy. J Endod. 23 (12), 748–750.

2 Vescovi, P., Manfredi, M., Mergio E., Meleti, M., Fornaini, C., Rocca J.P., Nammour, S. (2010). Surgical approach with Er:YAG laser on osteonecrosis of the jaws (ONJ) in patients under bisphosphonate therapy (BPT). Lasers Med Sci. 25(1):101-13.

3 Cohn, S.A. (1998). When all else fails… Aust Endod J. 24, 128–129.

4 Setzer, F.C., Shah, S.B., Kohli, M.R., Karabucak B., Kim S. (2010). Outcome of Endodontic Surgery: A Meta-analysis of the Literature – Part 1: Comparison of

Traditional Root-end Surgery and Endodontic Microsurgery. J Endod 36 (11), 1757-1765.

5 v. Arx, T. (2005). Failed root canals: The case for apicoectomy (periradicular surgery). J Oral Maxillofac Surg. 63, 832–837.

6 Mohammadi, Z. (2009). Laser applications in endodontics: an update review. Int Dent J. 59 (1), 35–46.

7 Paghdiwala, A.F. (1993). Root resection of endodontically treated teeth by erbium:YAG laser radiation. J Endod. 19 (2), 91–94.

8 Hibst, R., Keller, U. (1989). Experimental studies of the application of the Er:YAG laser on dental hard substances: I. Measurement of the ablation rate. Lasers Surg Med. 9 (4), 338–344.

9 Komori, T., Yokoyama, K., Matsumoto, Y., Matsumoto, K. (1997). Erbium:YAG and holmium:YAG laser root resection of extracted human teeth. J Clin Laser Med Surg. 15 (1), 9–13.

10 Zhao, X.Y., Wang, S.M., Zhang, C.F. (2010). Root resection by Er:YAG laser: a scanning electron microscope study. Hua Xi Kou Qiang Yi Xue Za Zhi. 28 (5), 526–528.

11 Takeda, A., Anjo, T., Takashina, M., Ebihara, A., Suda, H. (2003). Apicoectomy using Er:YAG laser – a clinical study. ISC. 1248, 261–263.

12 Angiero, F., Benedicenti, S., Signore, A., Parker, S., Crippa, R. (2011). Apicoectomies with the Erbium Laser: A complementary technique for retrograde endodontic treatment. Photomed Laser Surg. 29 (12), 845–849.

13 Kesler, G., Shvero, D.K., Tov, Y.S, Romanos, G. (2011). Platelet derived growth factor secretion and bone healing after Er:YAG laser bone irradiation. J Oral Implantol. 37(No. sp1):195-204.

14 Aleksic, V., Aoki, A., Iwasaki, K., Takasaki, A.A., Wang, C.Y., Abiko, Y., Ishikawa, I., Izumi, Y. (2012). Low-level Er:YAG laser irradiation enhances osteoblast proliferation through activation of MAPK/ERK. Lasers Med Sci. 25(4):559-569.

15 Luomanen, M., Meurmann, J.H. (1986). Laser-induced alterations in rat oral mucosa. Scand J Dent Res. 94(5):452-60

16 Jin, J.Y., Lee, S.H., Yoon, H.J. (2010). A comparative study of wound healing following incision with a scalpel, diode laser or Er,Cr:YSGG laser in guinea pig oral mucosa: A histological and immunohistochemical analysis. Acta Odontol Scand. 68(4):232-8

17 Merigo, E., Clini, F., Fornaini, C. et. al. (2012). Laser-assisted surgery with different wavelength: a preliminary ex vivo study on thermal increase and histological evaluation. Lasers Med Sci (DOI: 10.1007/s10103-012-1081-8)

18 Pandurić, D.G., Bago, I. Katanec, D., Zabkar, J. Miletić, I., Anić, I. (2012). Comparison of Er:YAG laser and surgical drill for osteotomy in oral surgery: An experimental study. J Oral Maxillofac Surg 70(11):2515-21.

19 Martins, G.L., Puricelli, E., Baraldi, C.E., Pononi, D. (2011). Bone healing after bur and Er:YAG laser ostectomies. J Oral Maxillofac Surg 69(4):1214-20.

20 Rotundo, R., Nieri, M., Cairo F., et al. (2010). Lack of adjunctive benefit of Er:YAG laser in non-surgical periodontal treatment: a randomized split-mouth clinical trial. J Clin Periodontol. 37 (6), 526–533.

21 Aoki, A., Ando, Y., Watanabe, H., Ishikawa, I. (1994). In vitro studies on laser scaling of subgingival calculus with an erbium:YAG laser. J Periodontol. 65 (12), 1097–1106.

22 Takeda, F.H., Harashima, T., Kimura, Y., Matsumoto, K. (1998). Efficacy of Er:YAG laser irradiation in removing debris and smear layer on root canal walls. J Endod. 24 (8), 548–551.

23 Stock, K., Hausladen, F., Hibst, R. (2012). Investigation on the potential of a novel diode pumped Er:YAG laser system for dental applications. Proc. SPIE. 8208, 82080D-82080D-7.

24 Carr, G.B., Murgel, C.A.F. (2010). The use of the operating microscope in endodontics. Dent Clin N Am. 54 (2), 191–214.

25 Del Fabbro, M., Taschieri, S. (2010). Endodontic therapy using magnification devices: a systematic review. J Dent. 38 (4), 269–275.

26 Setzer, F.C., Kohli, M.R., Shah, S.B., Karabucak, B., Kim, S. (2012). Outcome of endodontic surgery: a meta-analysis of the literature – Part 2: Comparison of endodontic microsurgical techniques with and without the use of higher magnification. J Endod. 38 (1), 1–10.

27 Fornaini, C., Riceputi, L.L.-P., Rocca J.P. (2012). Patient responses to Er:YAG laser when used for conservative dentistry. Lasers Med Sci 27:1143-1149

3 Erklärung des Eigenanteils

Hiermit erkläre ich, Markus Lietzau, dass die vollständige Datenerhebung, Datenanalyse sowie das Verfassen der vorliegenden Veröffentlichung von mir selbst durchgeführt wurde. Die Ko-Autoren waren beratend sowie korrigierend tätig. Der Doktorvater sowie der Betreuer dieser Publikationspromotion waren zudem an der Erstellung der Projektskizze beteiligt.

4 Danksagung

Für die wissenschaftliche Betreuung möchte ich mich ganz herzlich bei Herrn Prof. Dr. Dr. Max Heiland und Herrn Prof. Dr. Dr. Ralf Smeets bedanken.

Herrn Prof. Dr. Christian Apel gilt mein ganz besonderer Dank für die stets freundliche Unterstützung, Motivation und hilfsbereite Betreuung bei der Planung und Durchführung der Arbeit.

5 Lebenslauf

6 Eidesstattliche Erklärung

Ich, Markus Lietzau erkläre, dass ich die vorgelegte Dissertationsschrift mit dem Thema: „Apicoectomy using Er:YAG laser in association with microscope: a comperative retrospective Investigation“ selbst verfasst und keine anderen als die angegebenen Quellen und Hilfsmittel benutzt, ohne die (unzulässige) Hilfe Dritter verfasst und auch in Teilen keine Kopien anderer Arbeiten dargestellt habe.“

Datum: 06.05.2013 Unterschrift